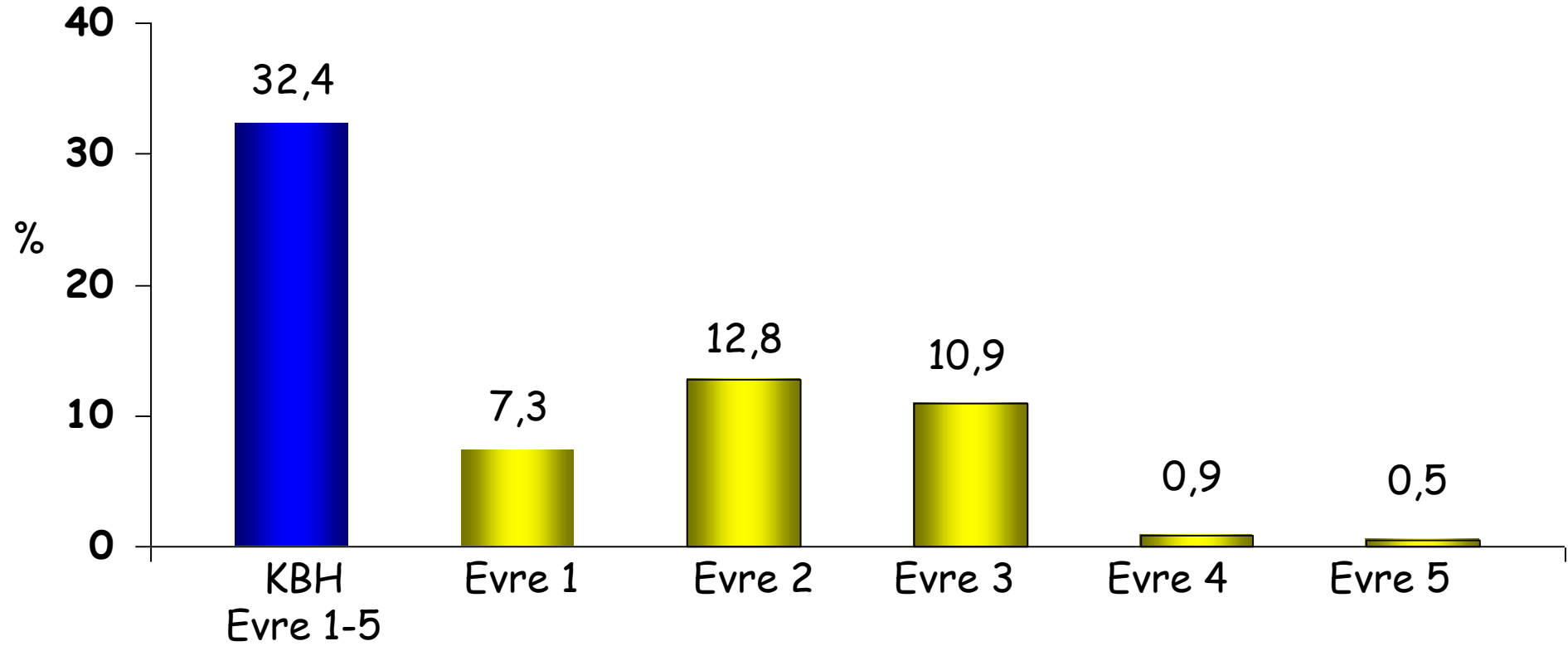




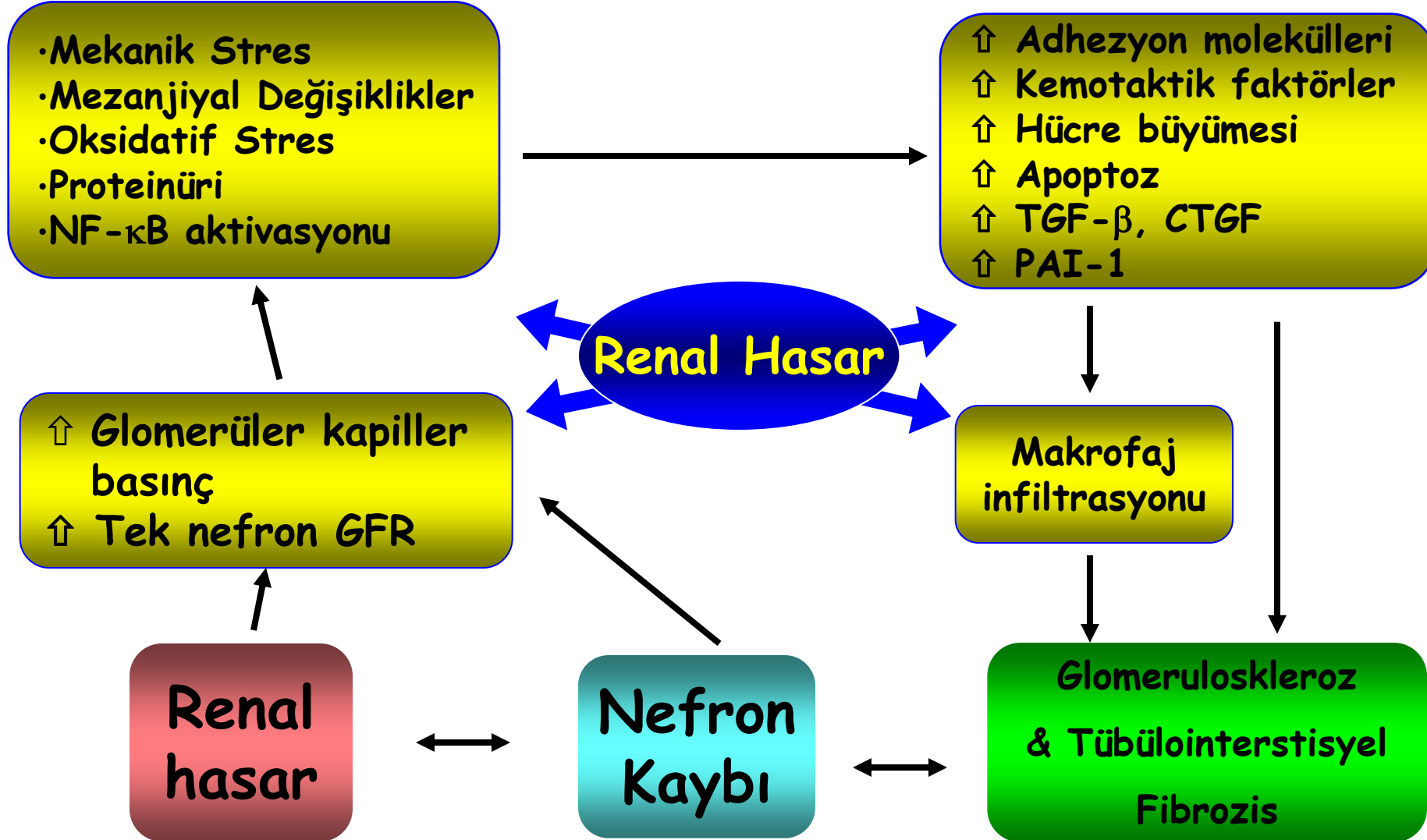
# DIYABETİK NEFROPATİDE HÜCRE BİYOLOJİSİ VE ANJİOPOETİNLERİN YERİ

Prof. Dr. Bülent ALTUN  
Hacettepe Üniversitesi Tıp Fakültesi  
İç Hastalıkları Anabilim Dalı  
Nefroloji Bilim Dalı

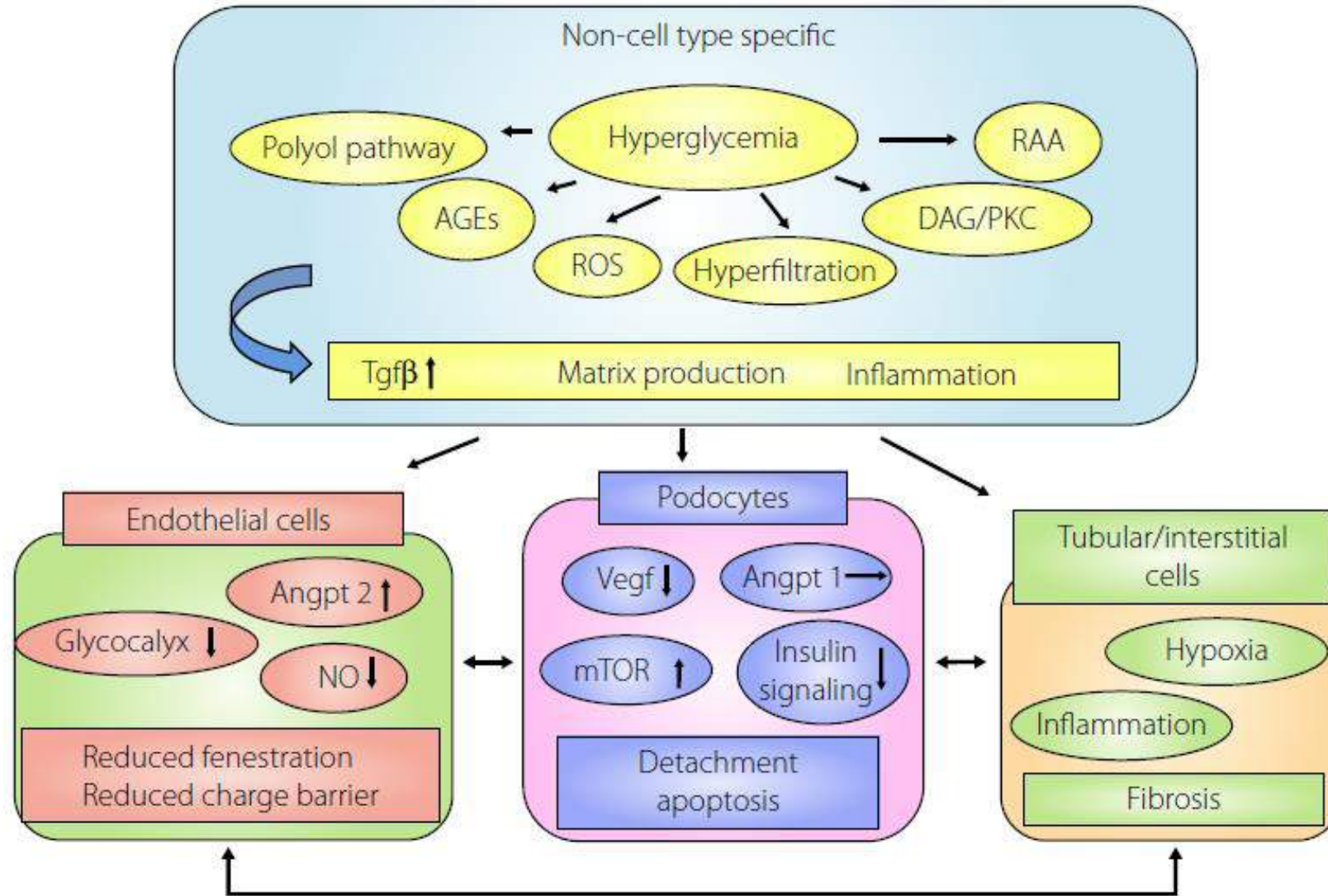
# Türkiyede Diyabetiklerde KBH



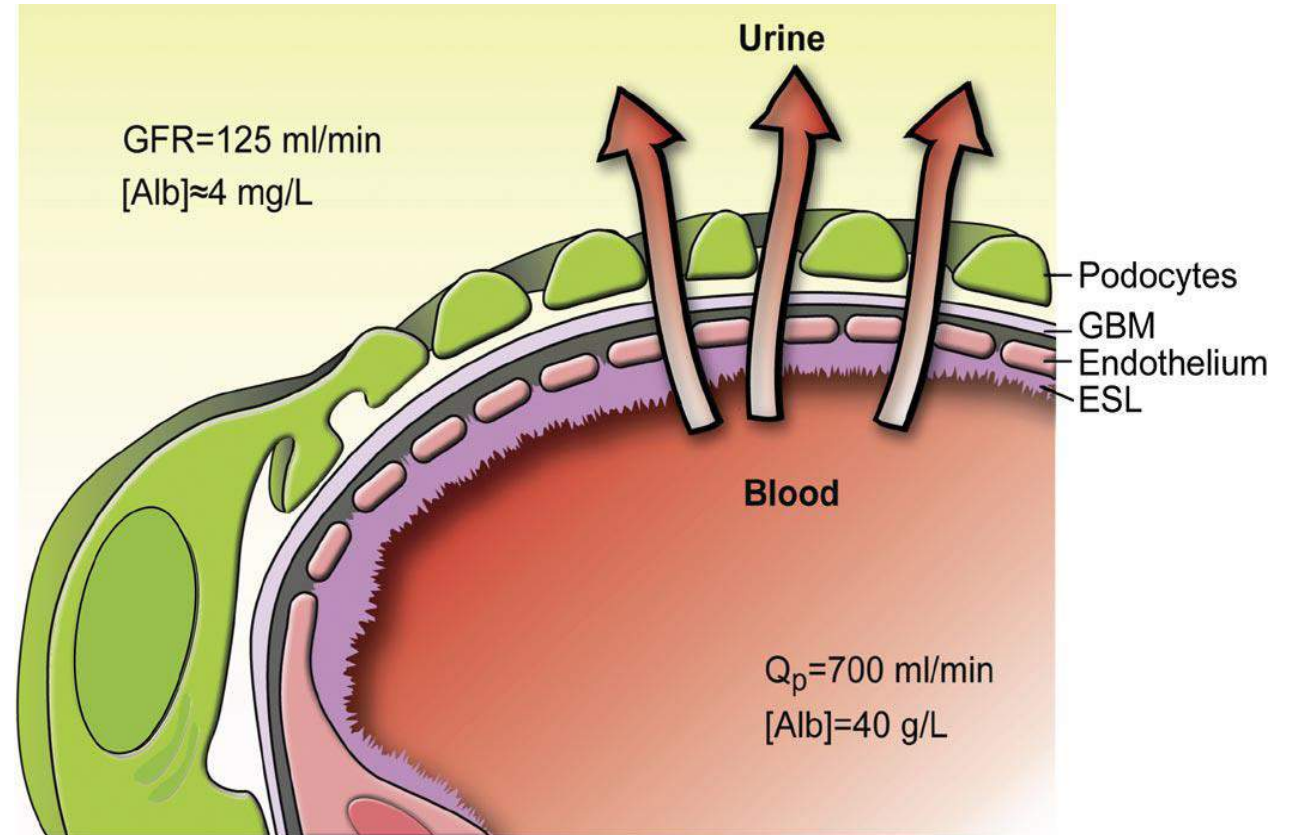
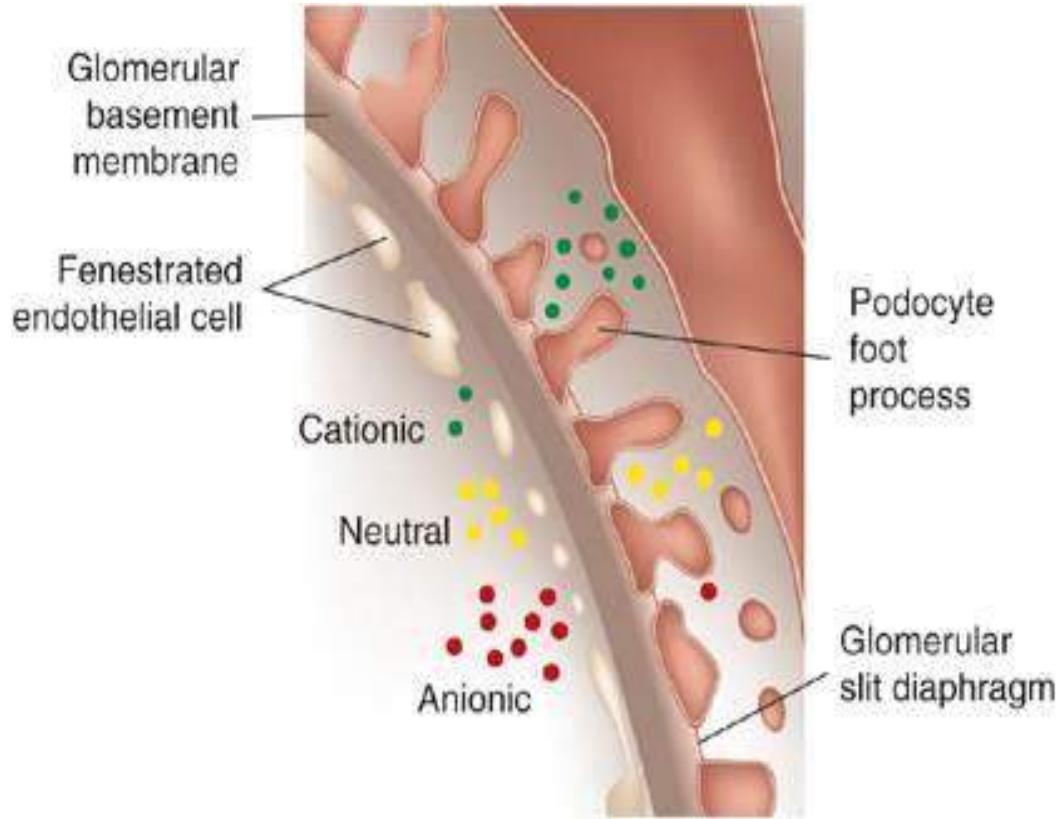
# Diyabetik Nefropati



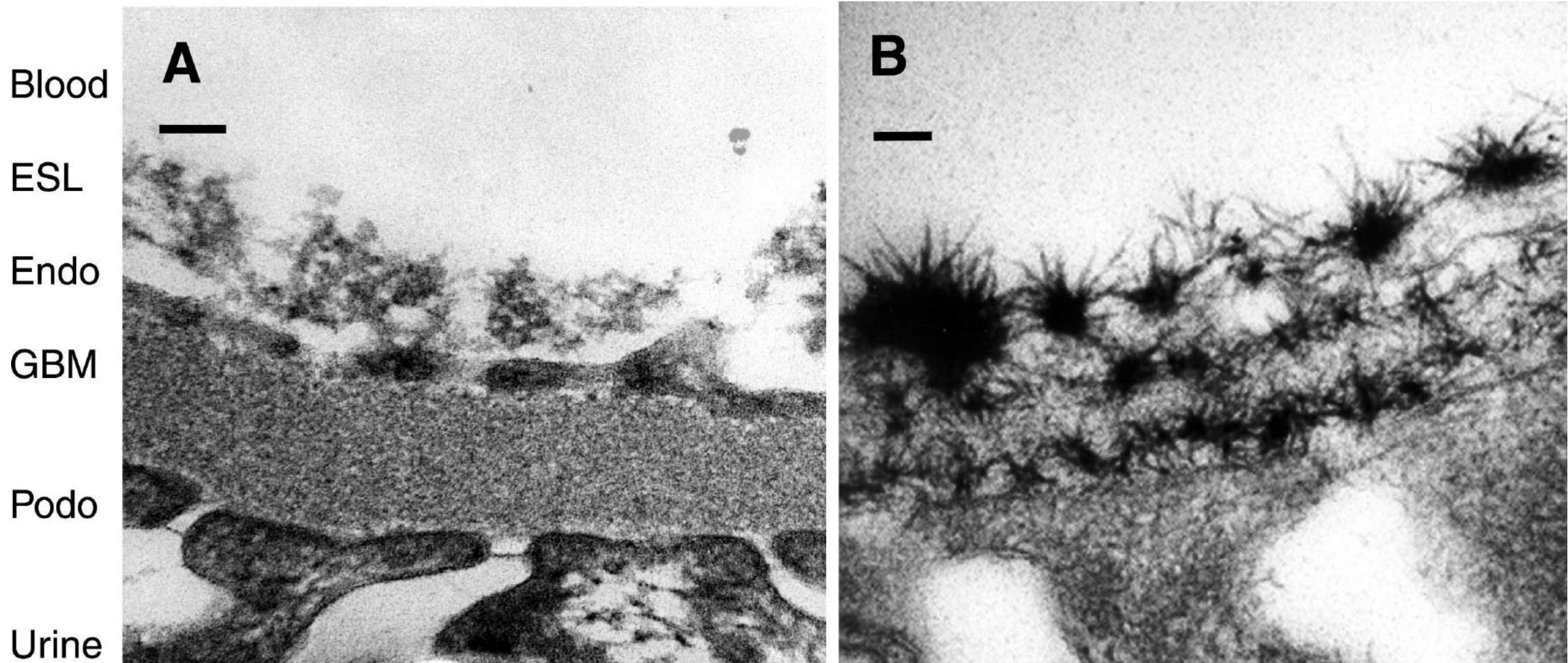
# Diyabetik Nefropati



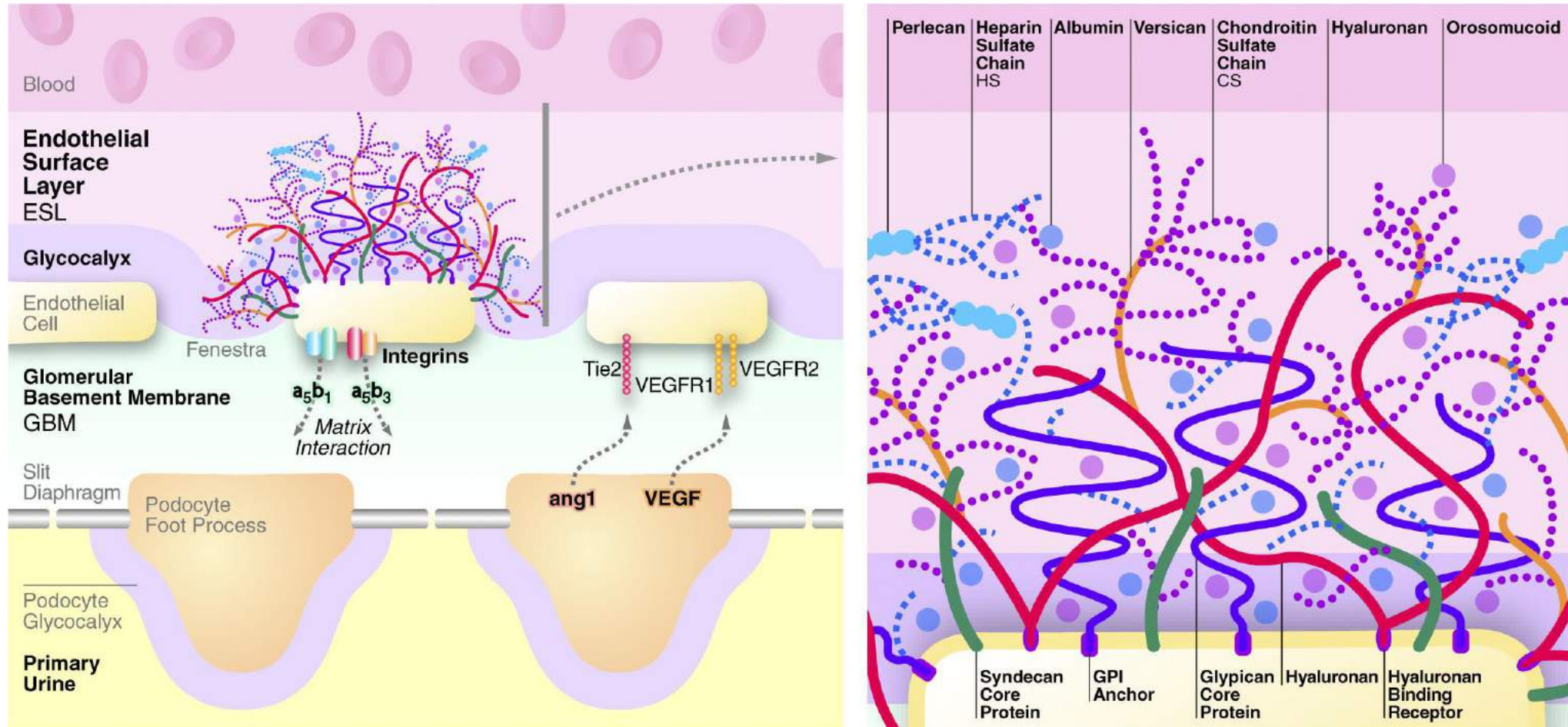
# Diyabetik Nefropati: Glomerüler Endotel Hücreleri



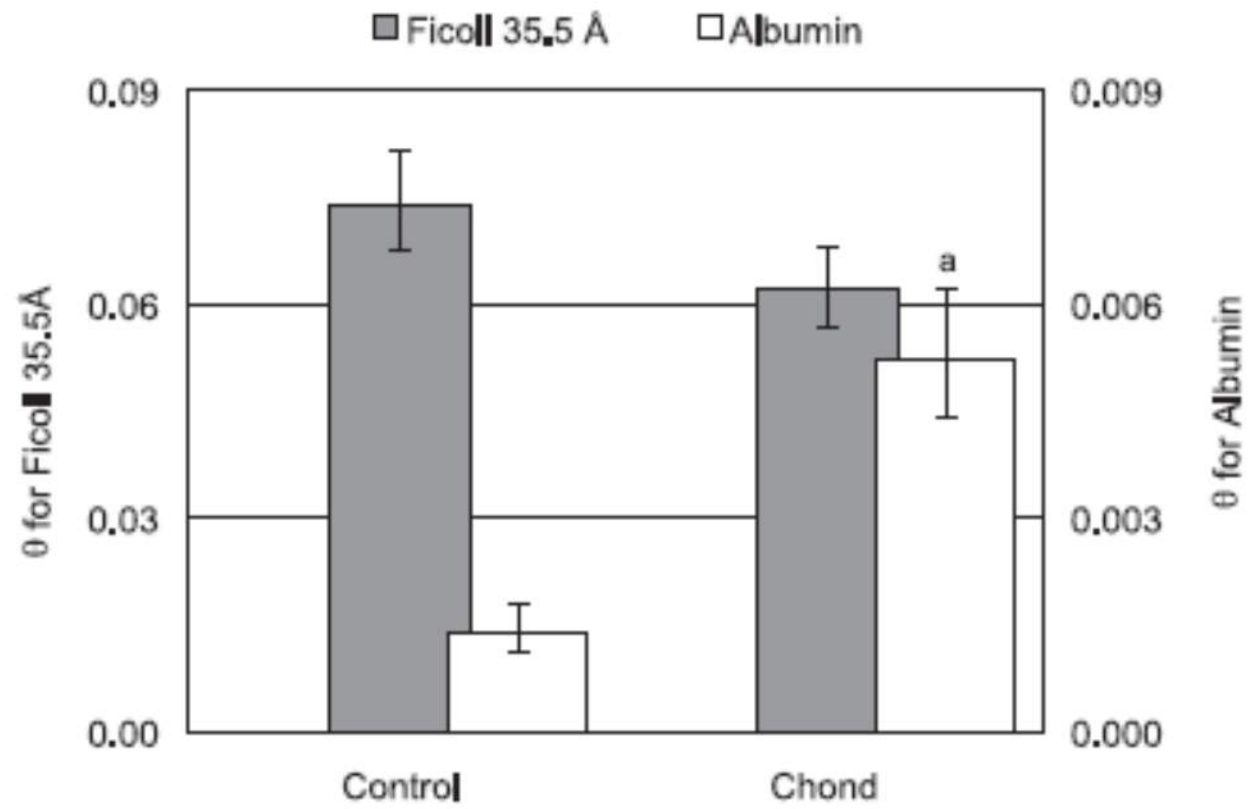
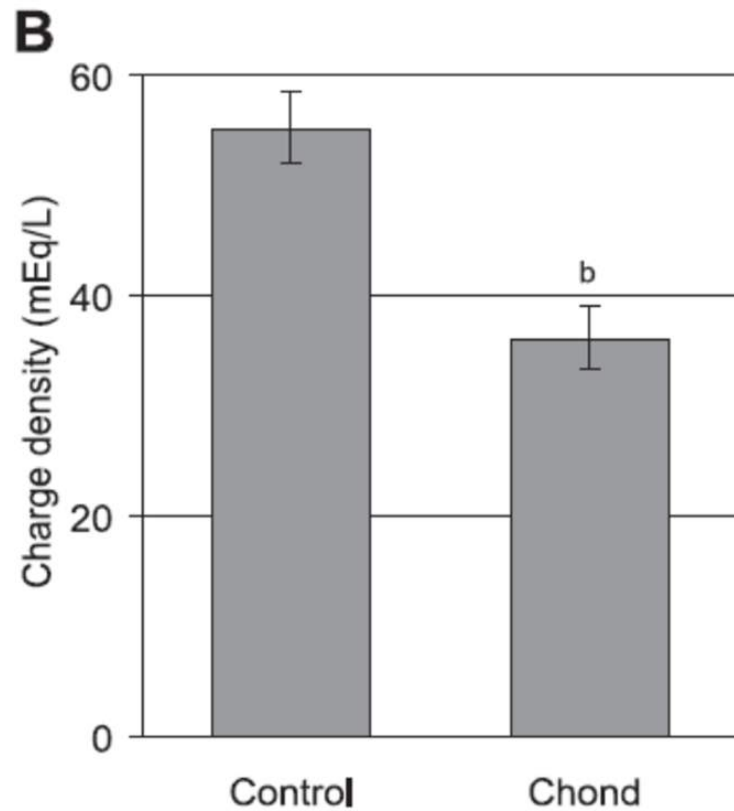
# Diyabetik Nefropati: Glomerüler Endotel Hücreleri



# Diyabetik Nefropati: Glomerüler Endotel Hücreleri

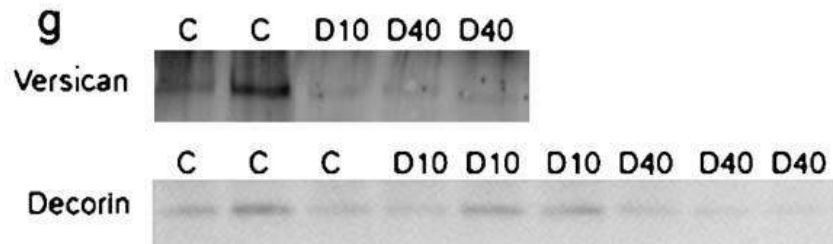
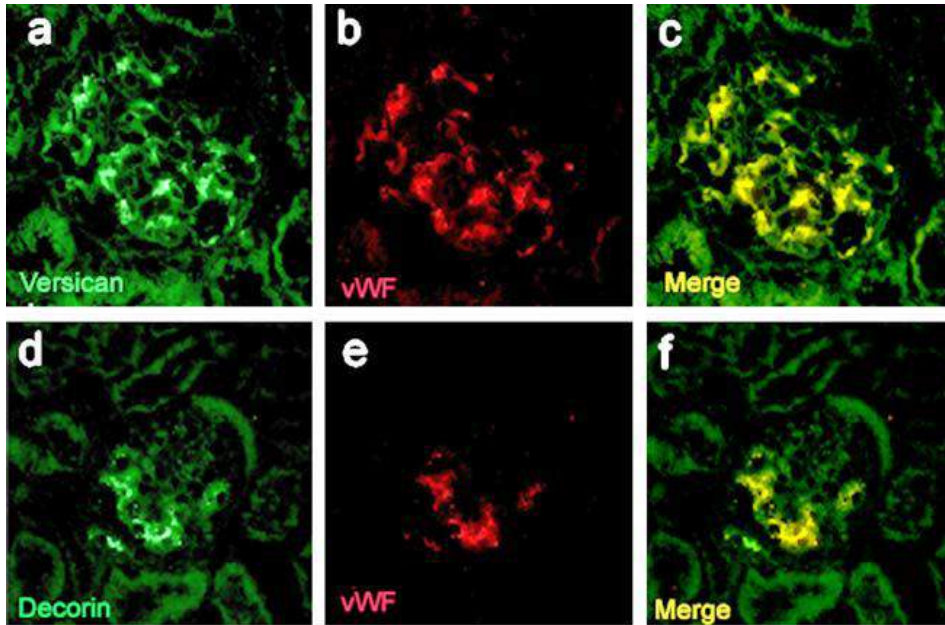


# Diyabetik Nefropati: Glomerüler Endotel Hücreleri

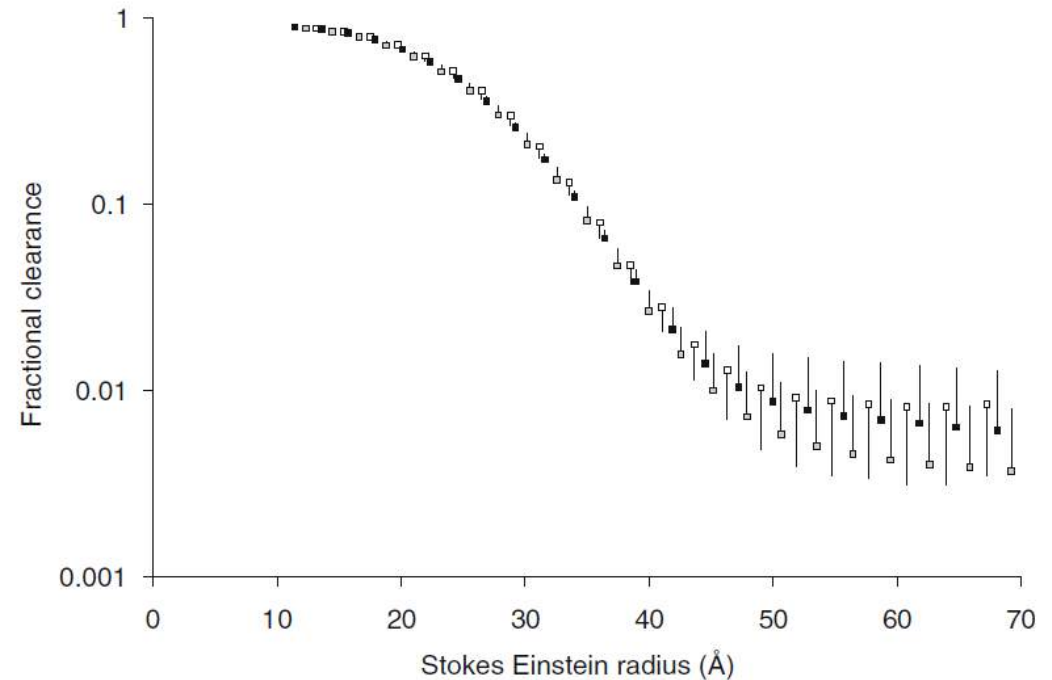




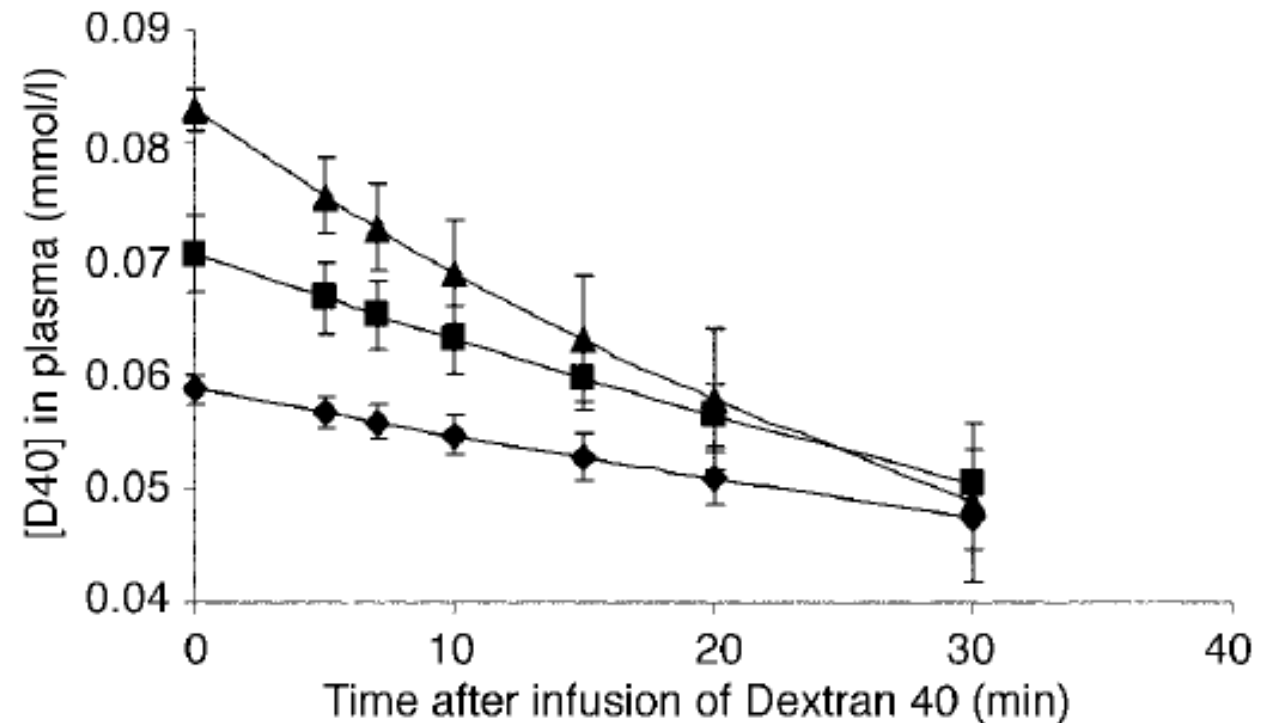
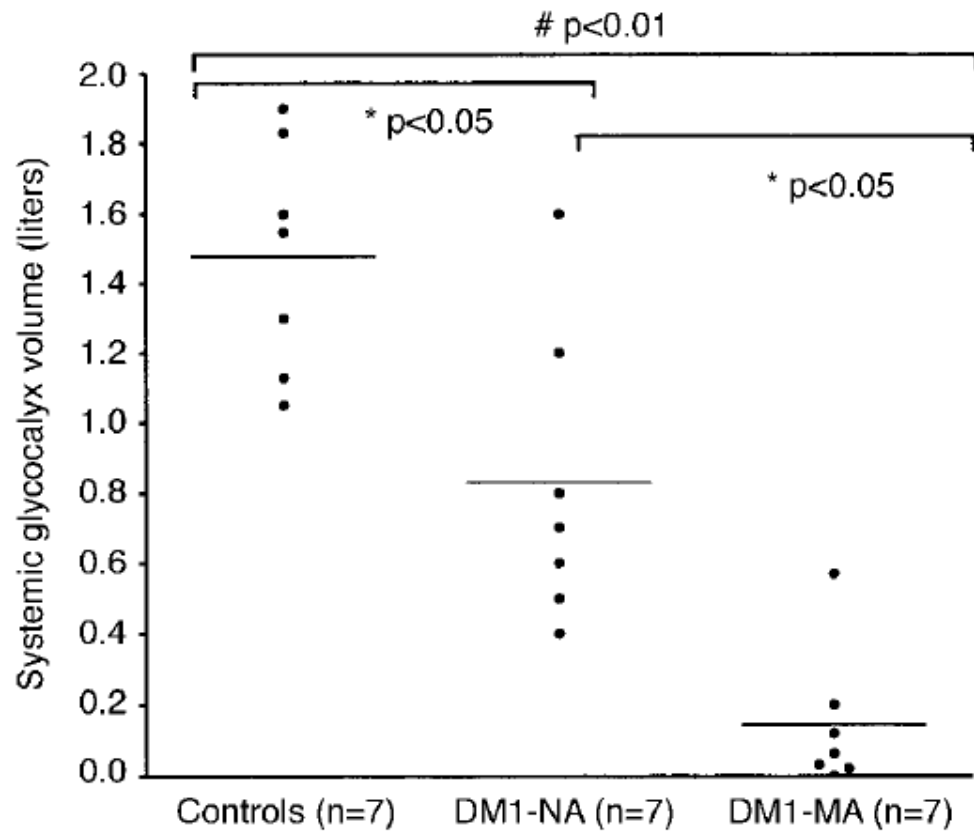
# Diyabetik Nefropati: Glomerüler Endotel Hücreleri



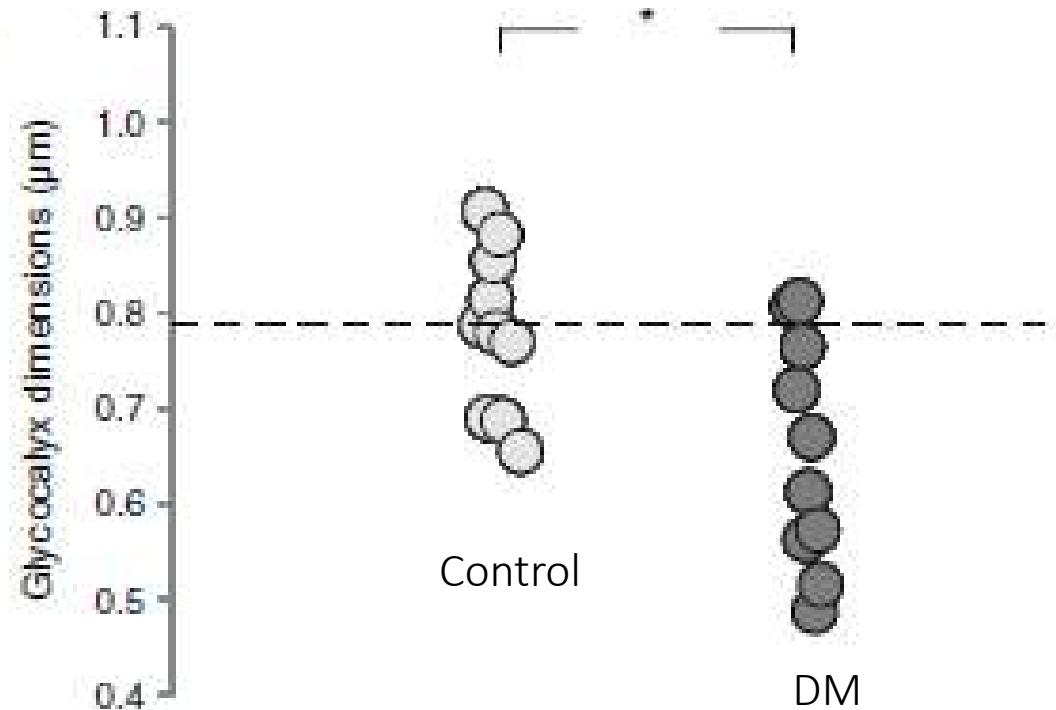
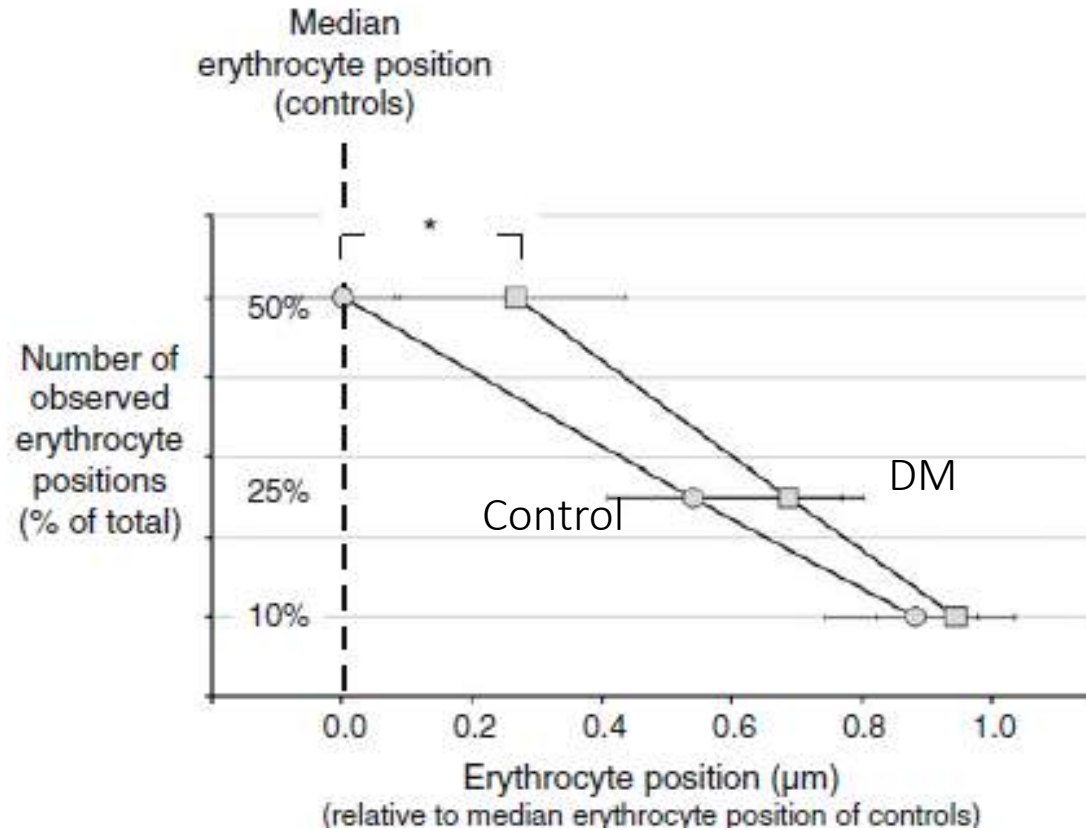
	$\theta_{\text{Albumin}} (\times 10^{-3})$	$\theta_{\text{Ficoll } 35.5 \text{ \AA}} (\times 10^{-3})$	$\theta_{\text{Ficoll } 55 \text{ \AA}} (\times 10^{-3})$	GFR ( $\text{ml}\cdot\text{min}^{-1}\cdot 100 \text{ gbw}^{-1}$ )
Control ( $n=6$ )	5.1 (3.1–7.8)	84 (70–102)	5.1 (1.6–15.8)	0.051 (0.026–0.097)
D10 ( $n=7$ )	2.7 (1.4–5.0)	72 (55–95)	2.7 (1.0–7.4)	0.137 (0.068–0.273) <sup>b</sup>
D40 ( $n=8$ )	16.0 (10.8–23.8) <sup>a</sup>	84 (78–91)	3.7 (1.7–8.2)	0.078 (0.050–0.123)



# Diyabetik Nefropati: Glomerüler Endotel Hücreleri

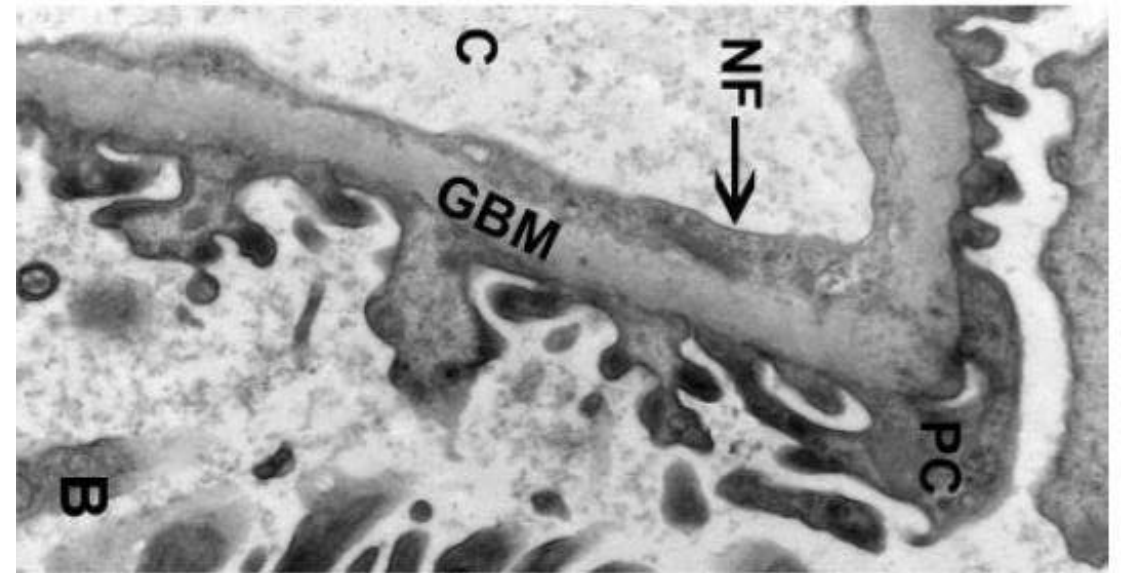
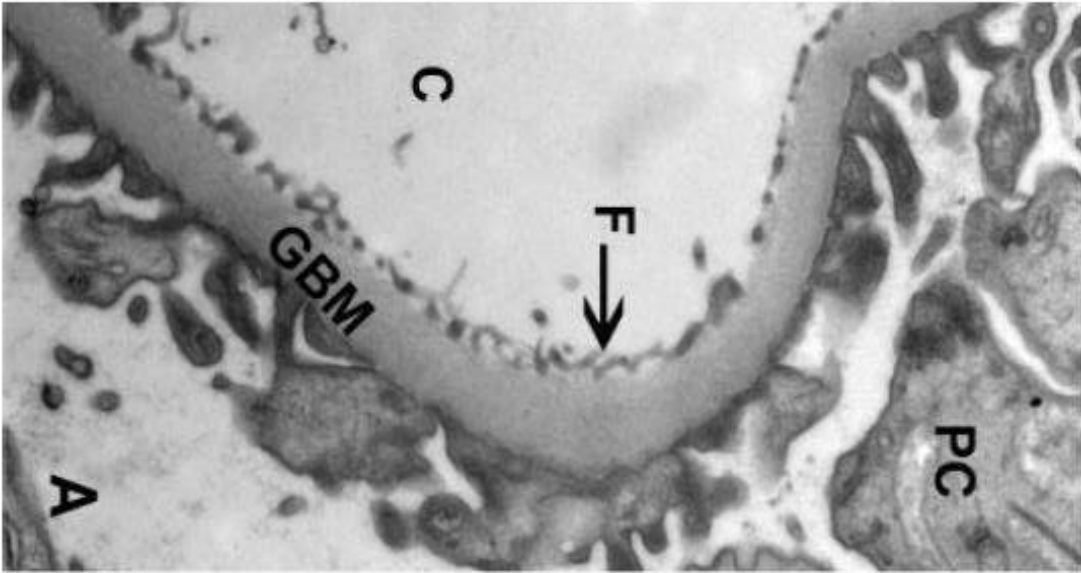


# Diyabetik Nefropati: Glomerüler Endotel Hücreleri

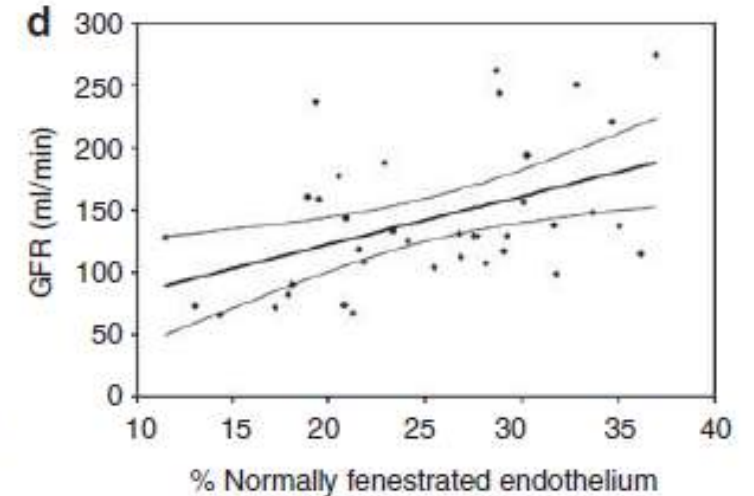
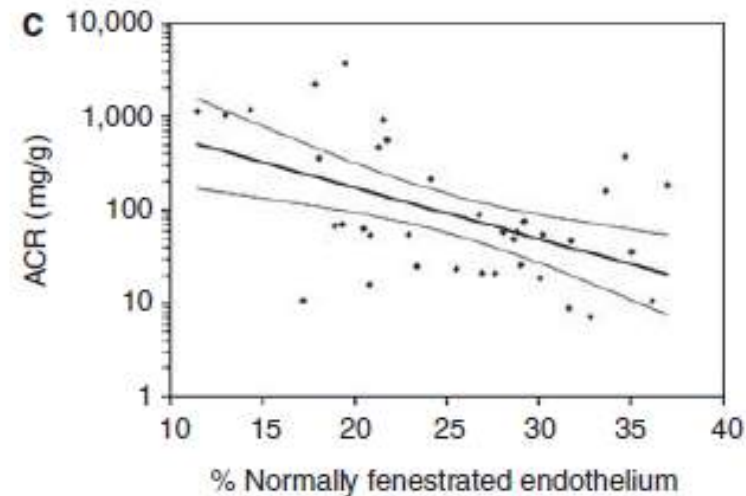
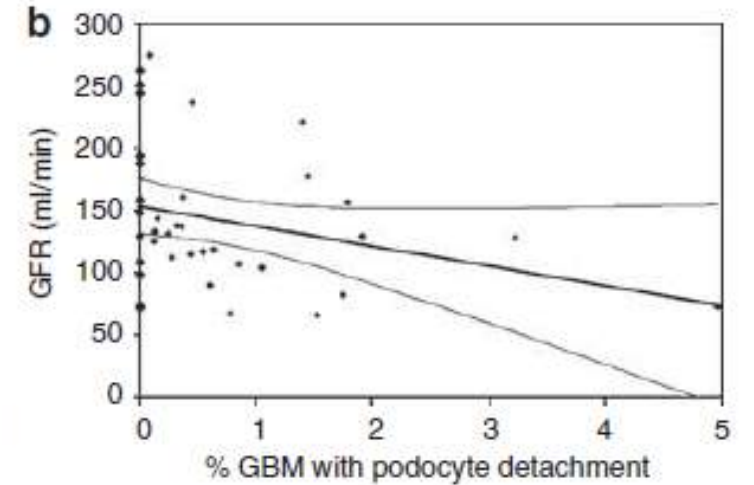
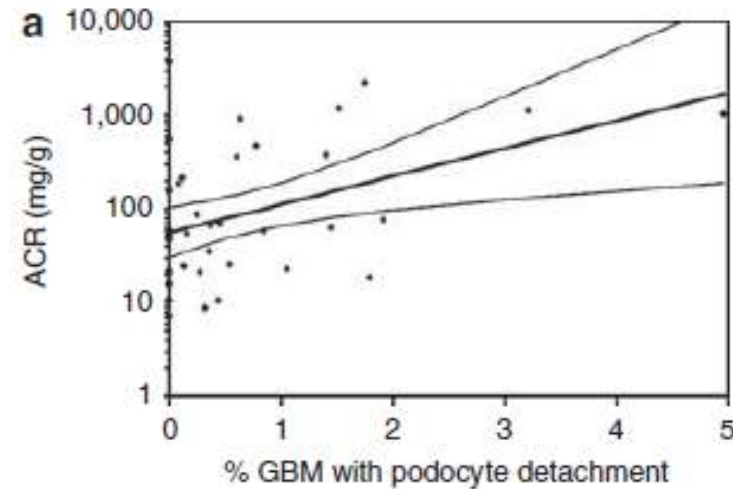
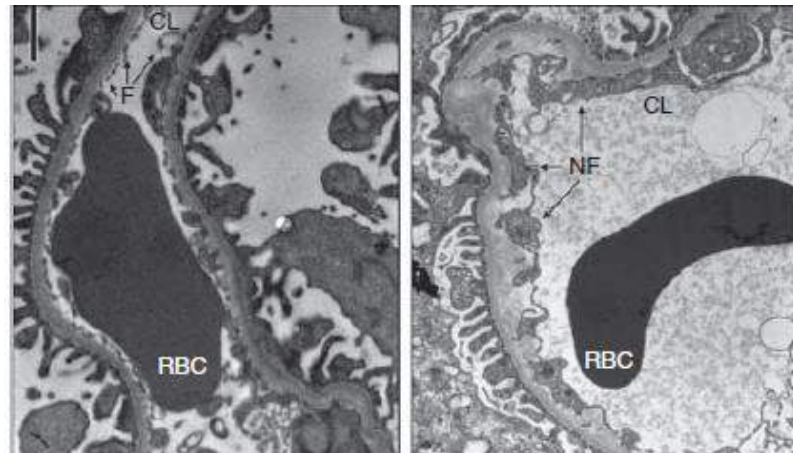
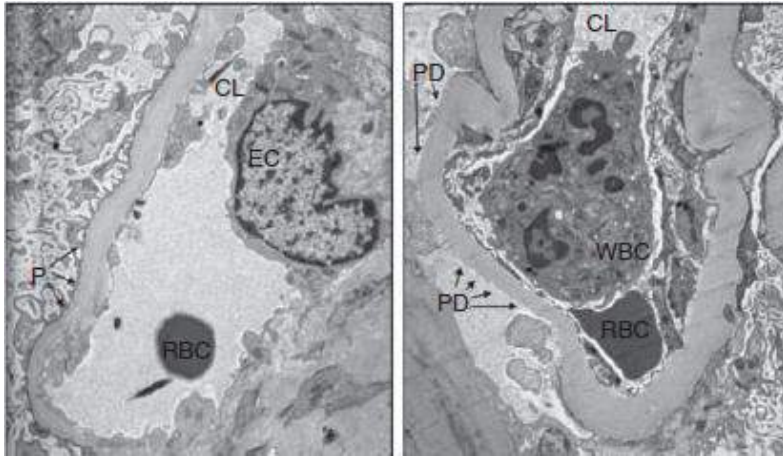


# Diyabetik Nefropati: Glomerüler Endotel Hücreleri

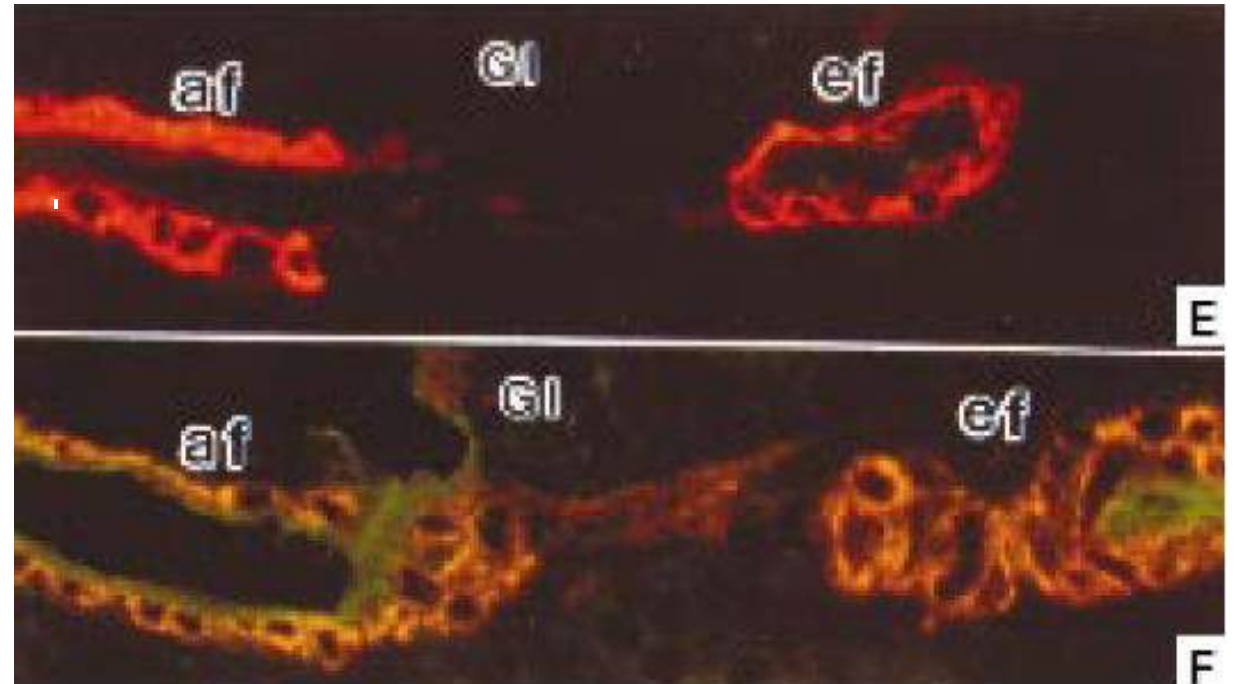
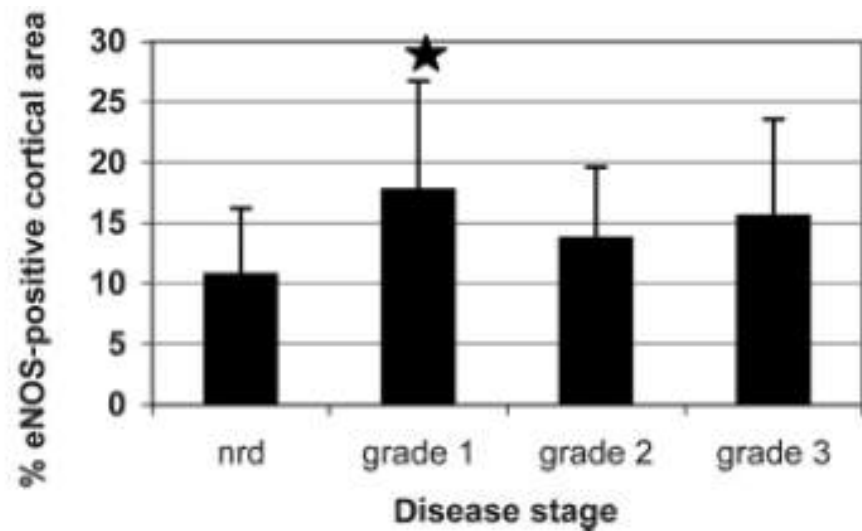
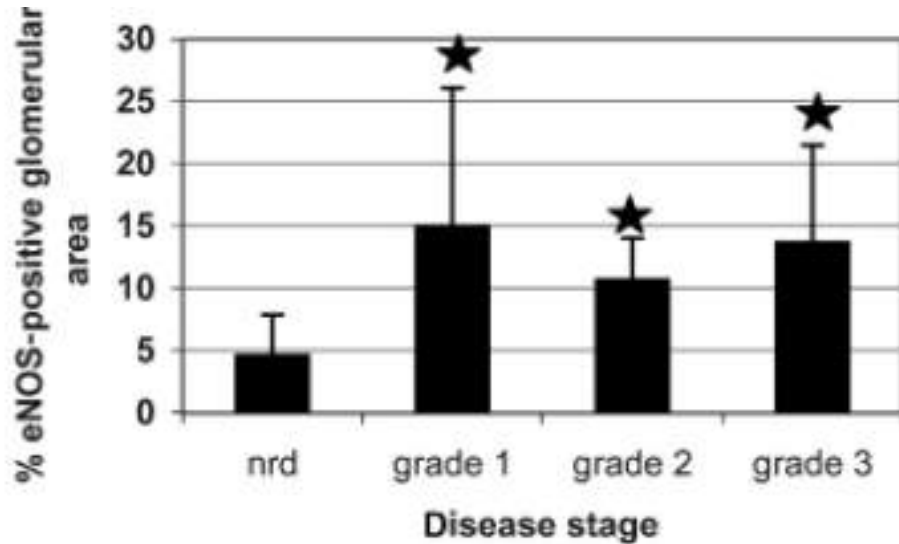
	C	NA	MA	P	P value
<i>n</i>	6	7	6	5	
S <sub>s</sub> (Fenestrated/cap) (%)	41 ± 11	32 ± 5	32 ± 3	25 ± 8	0.03,* 0.03,† 0.002‡



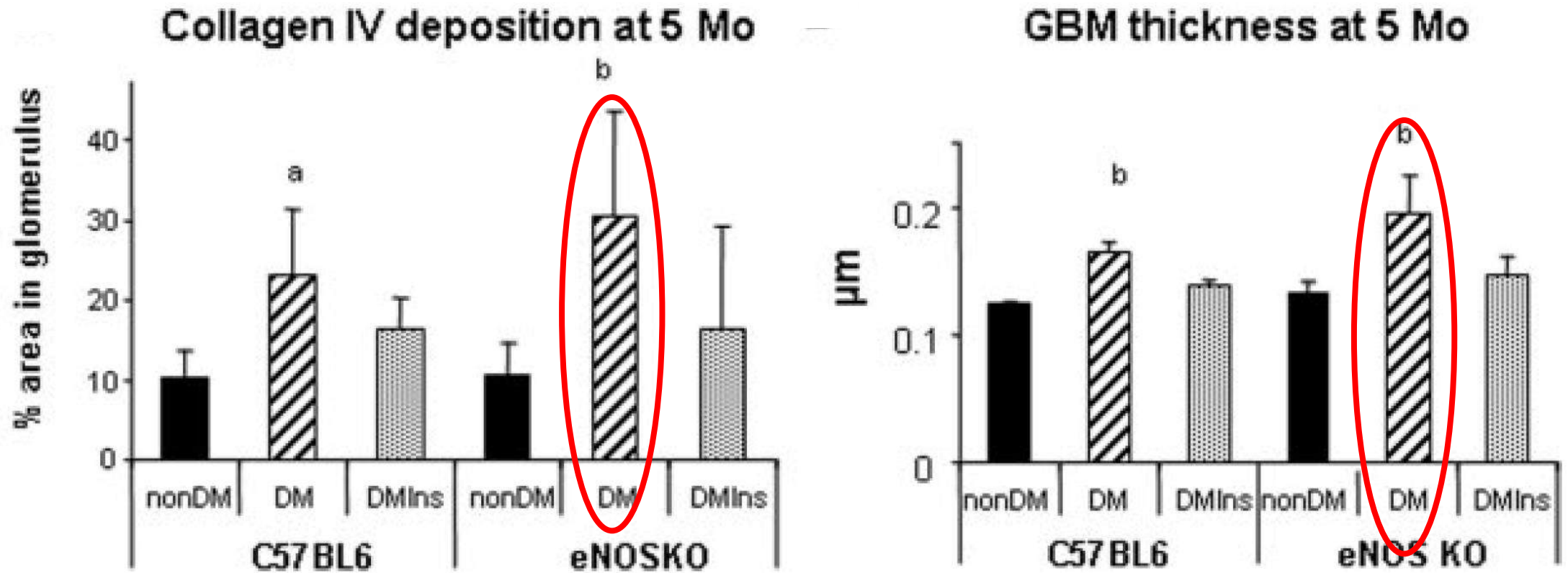
# Diyabetik Nefropati: Glomerüler Endotel Hücreleri



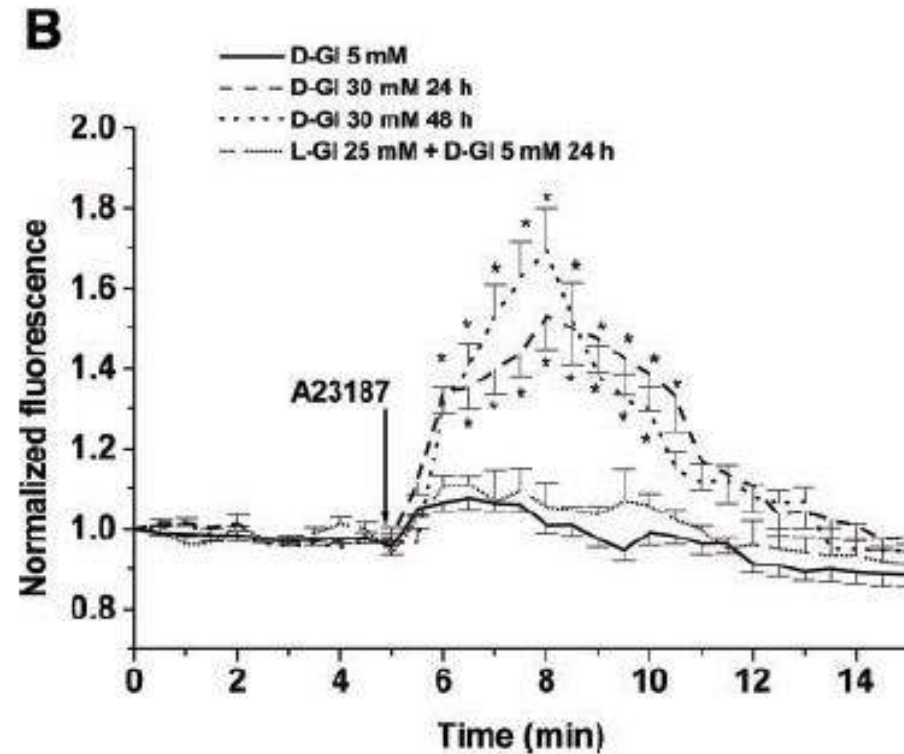
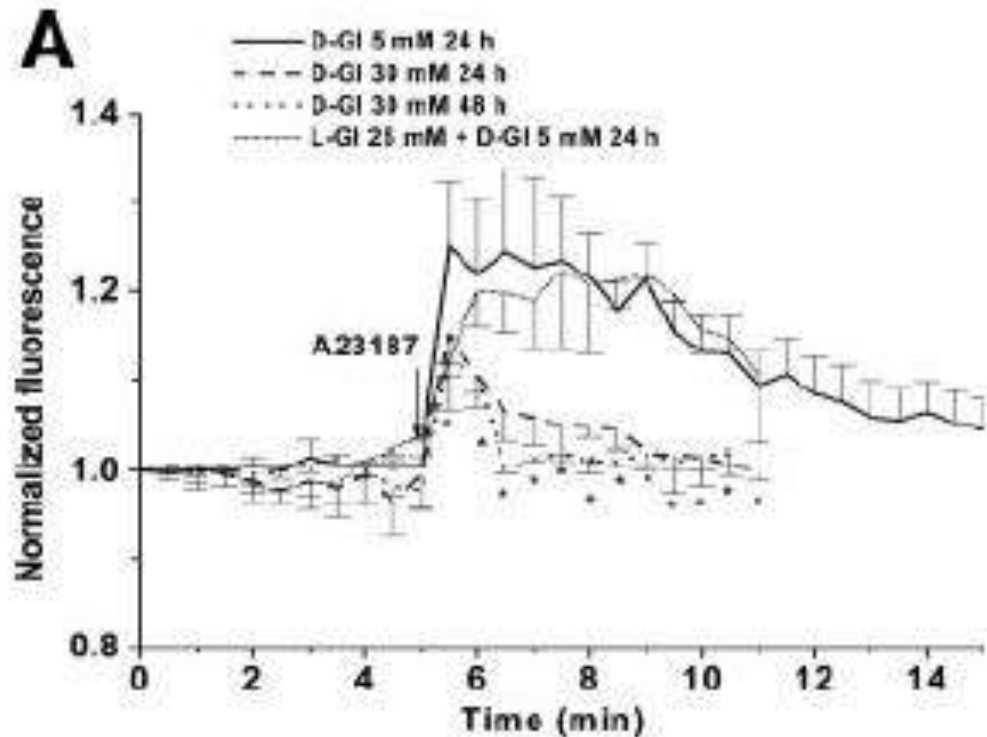
# Diyabetik Nefropati: Endotelyel Nitrik Oksit Sentetaz



# Diyabetik Nefropati: Endotelyel Nitrik Oksit



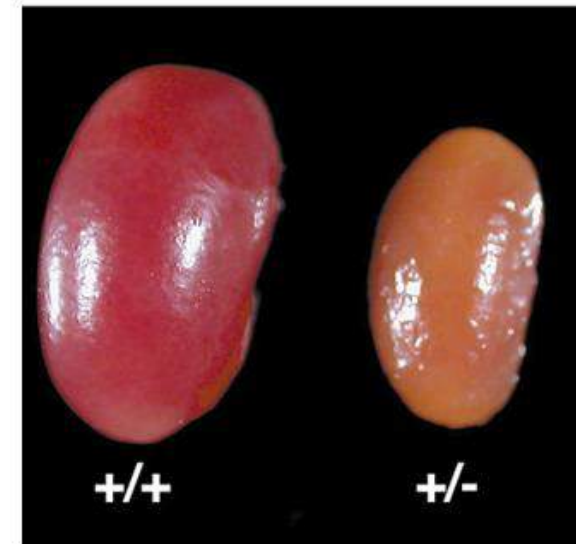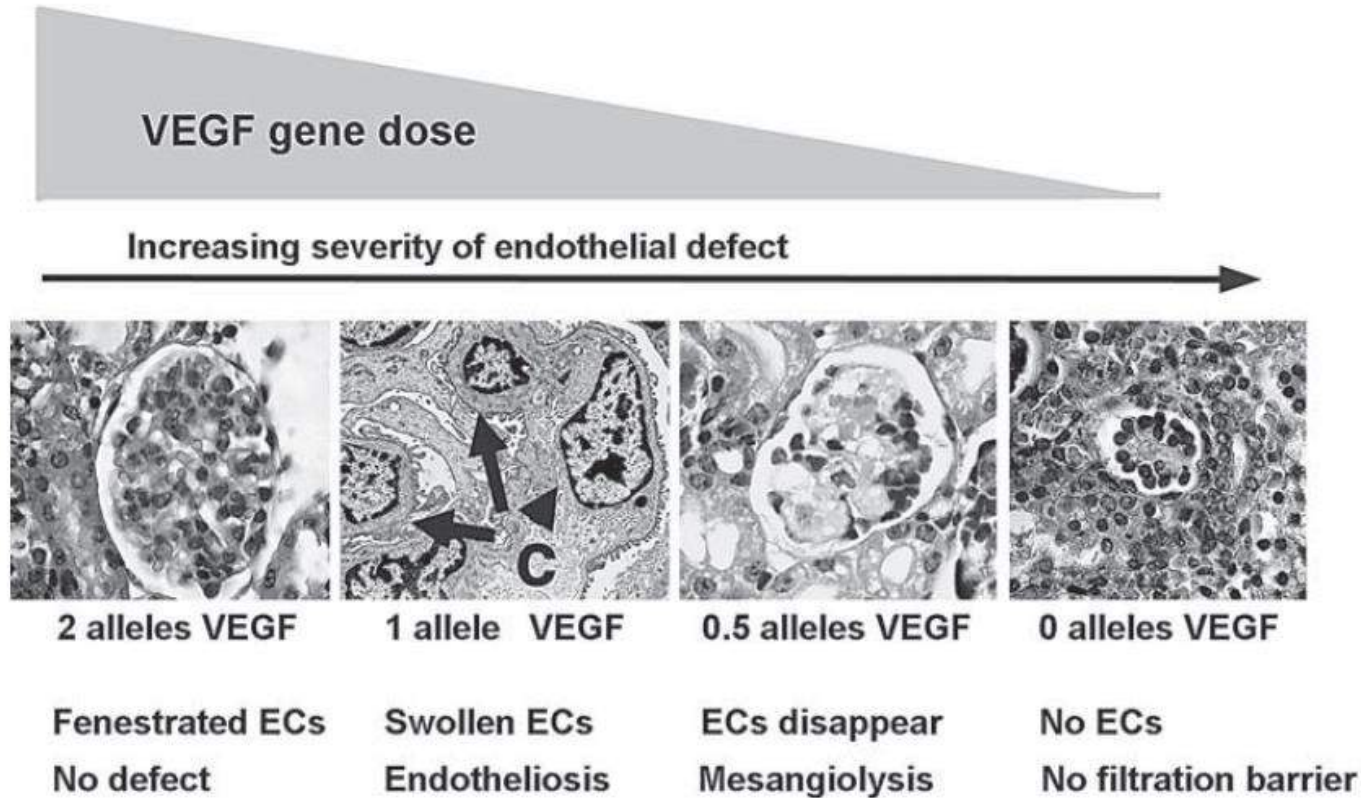
# Diyabetik Nefropati: Endotelyel Nitrik Oksit Sentetaz



Sergey V. B. ve ark. Am J Physiol Heart Circ Physiol 283: H2130-H2139, 2002.

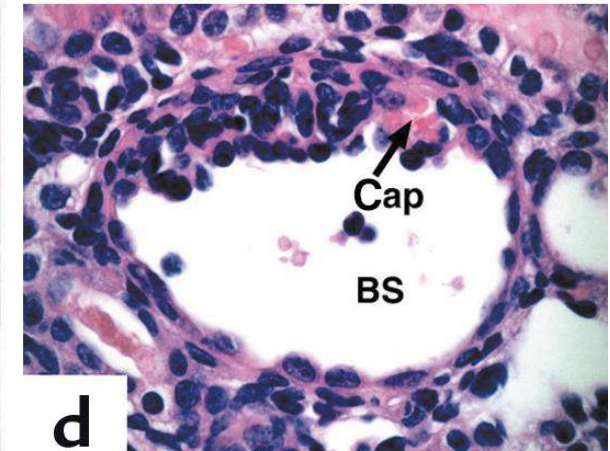
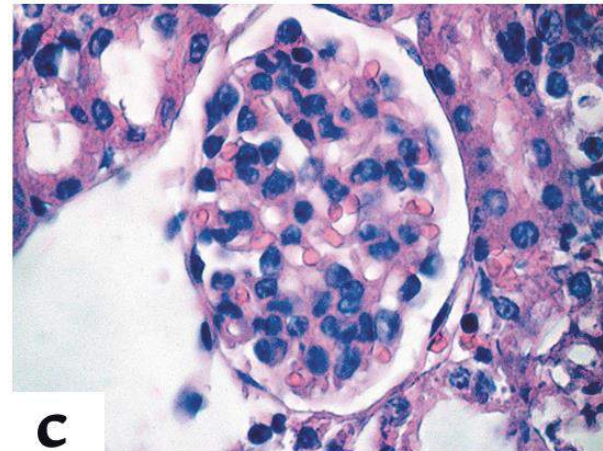
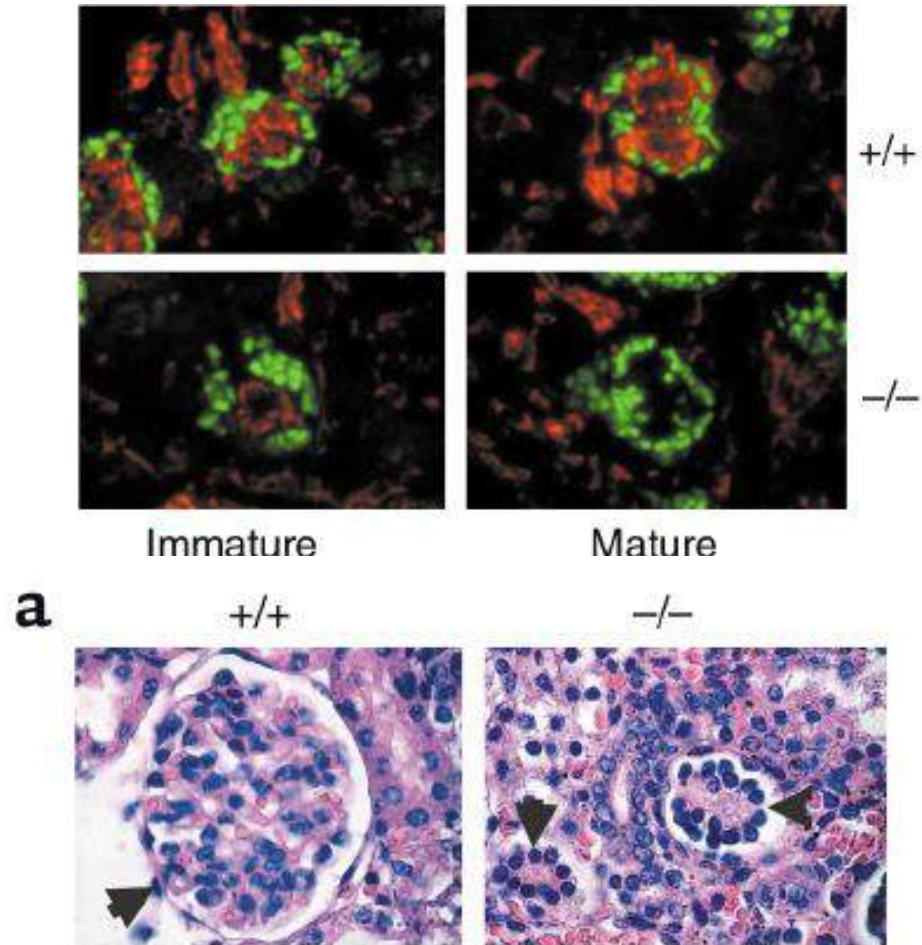


# Diyabetik Nefropati: Vasküler Endotelyal Büyüme Faktörü

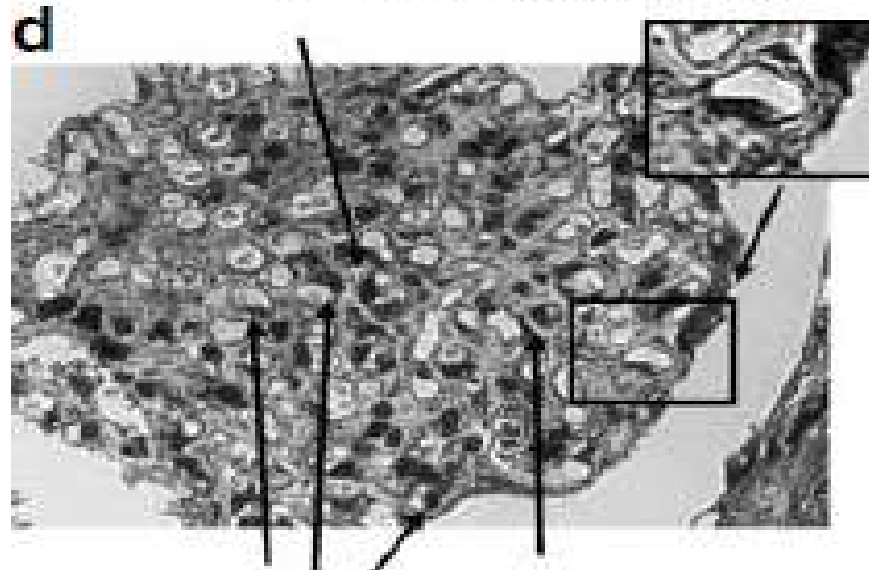
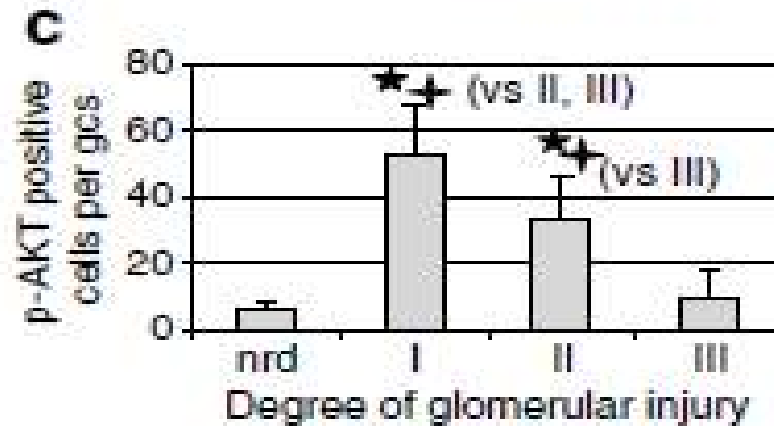
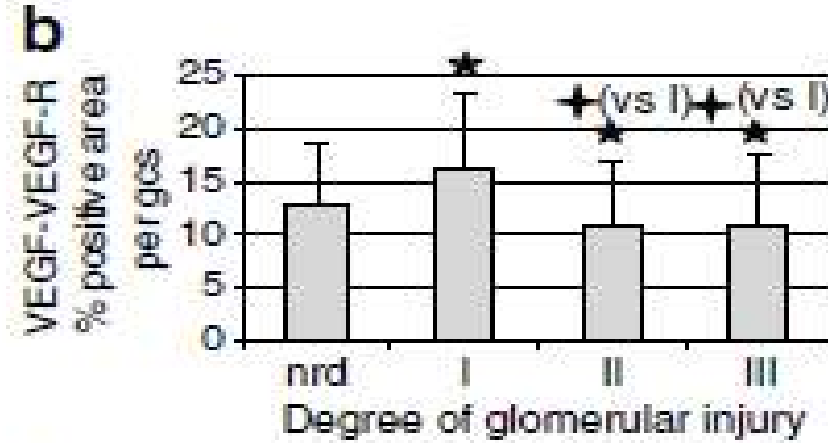
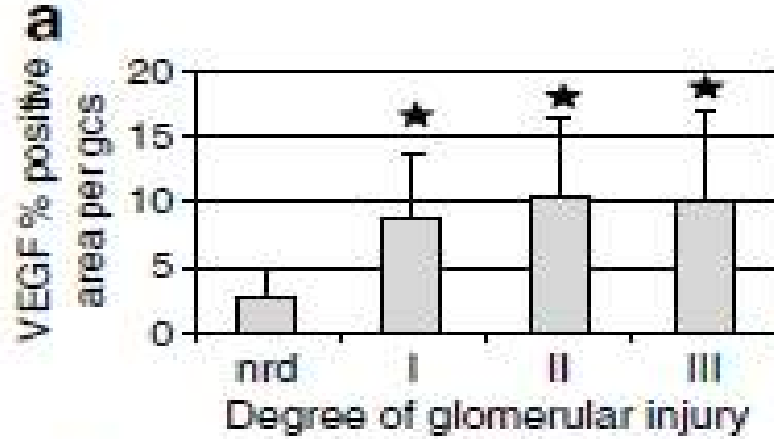


# VEGF alleles  
Endo defect  
Pathologic lesion

# Diyabetik Nefropati: Vasküler Endotelyal Büyüme Faktörü

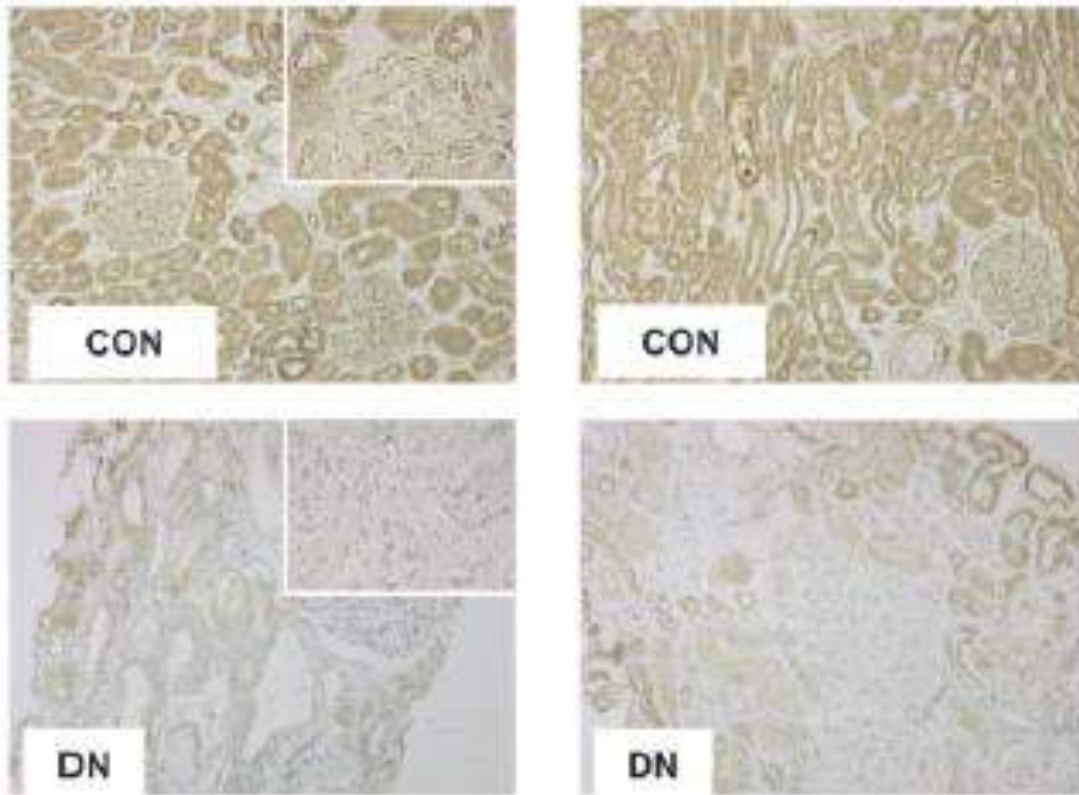


# Diyabetik Nefropati: Vasküler Endotelyal Büyüme Faktörü

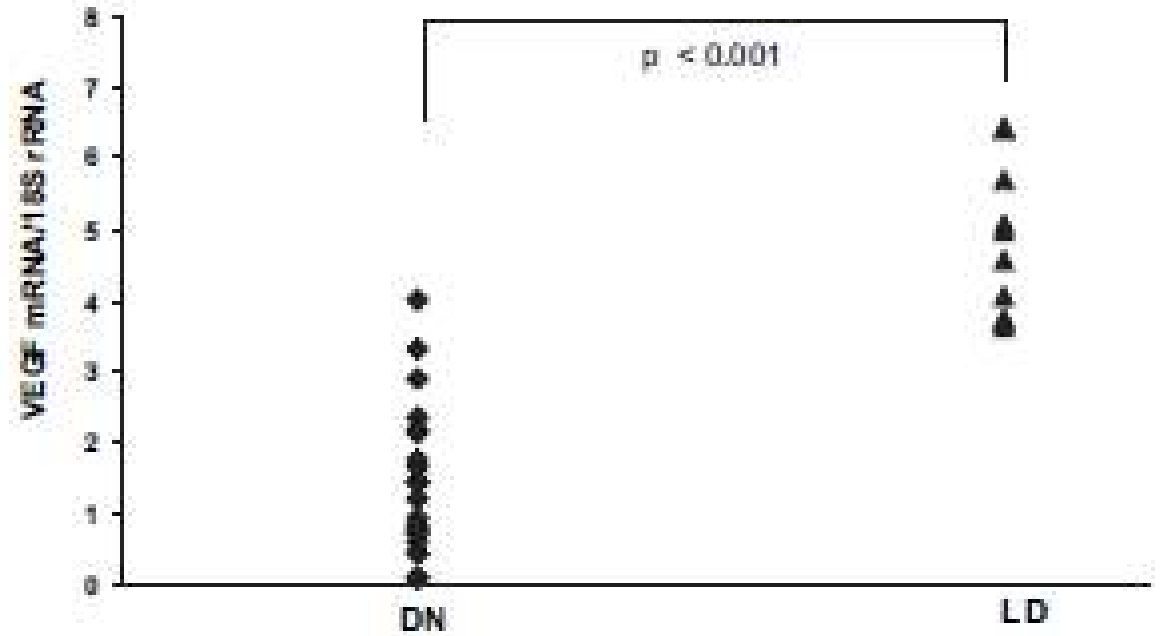


Hohenstein B. ve ark., *Kidney International* (2006) 69, 1654-1661.

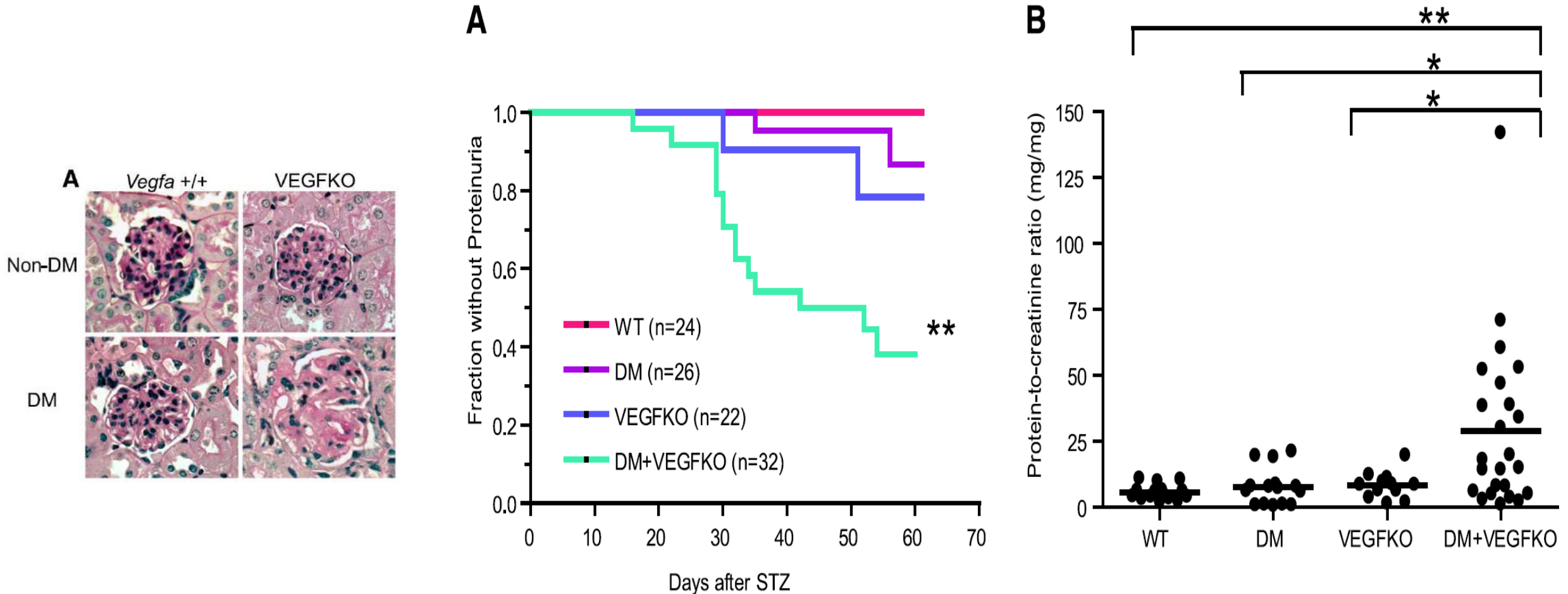
# Diyabetik Nefropati: Vasküler Endotelyel Growth Faktör



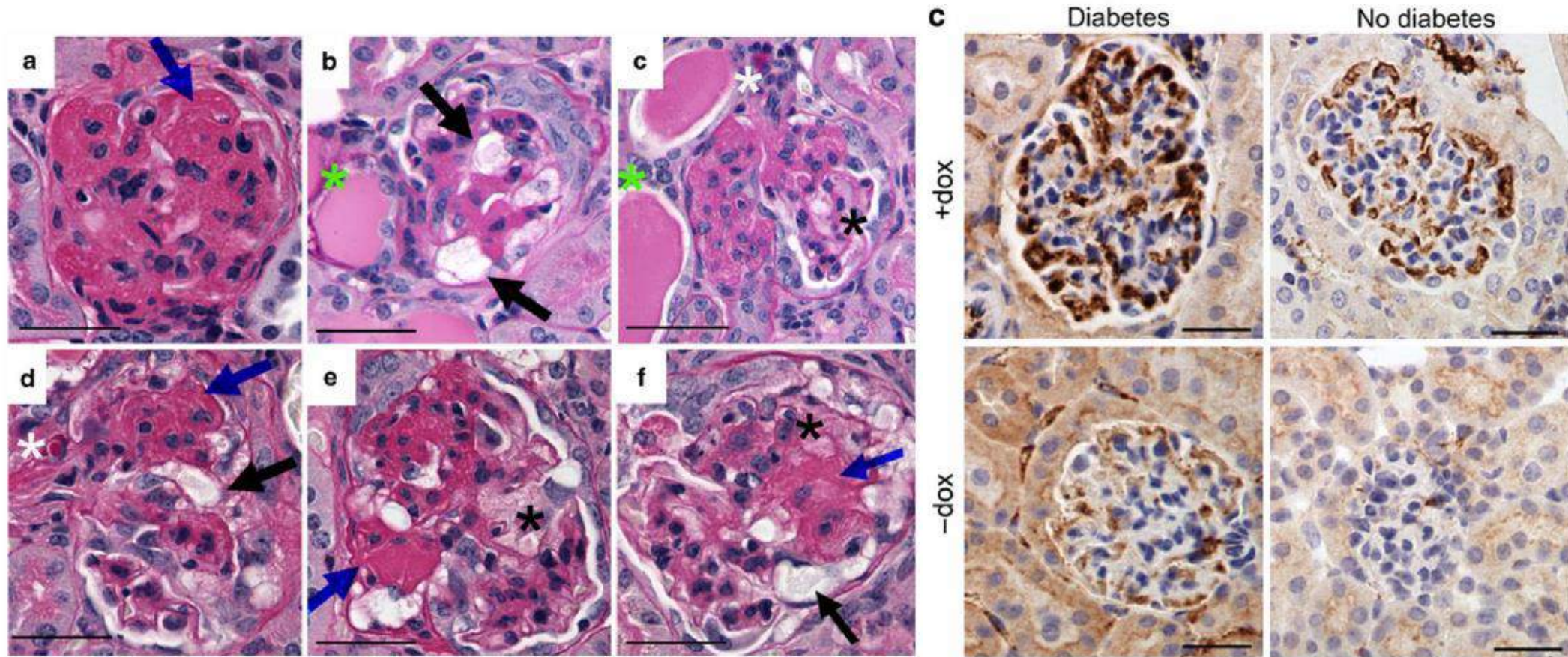
A



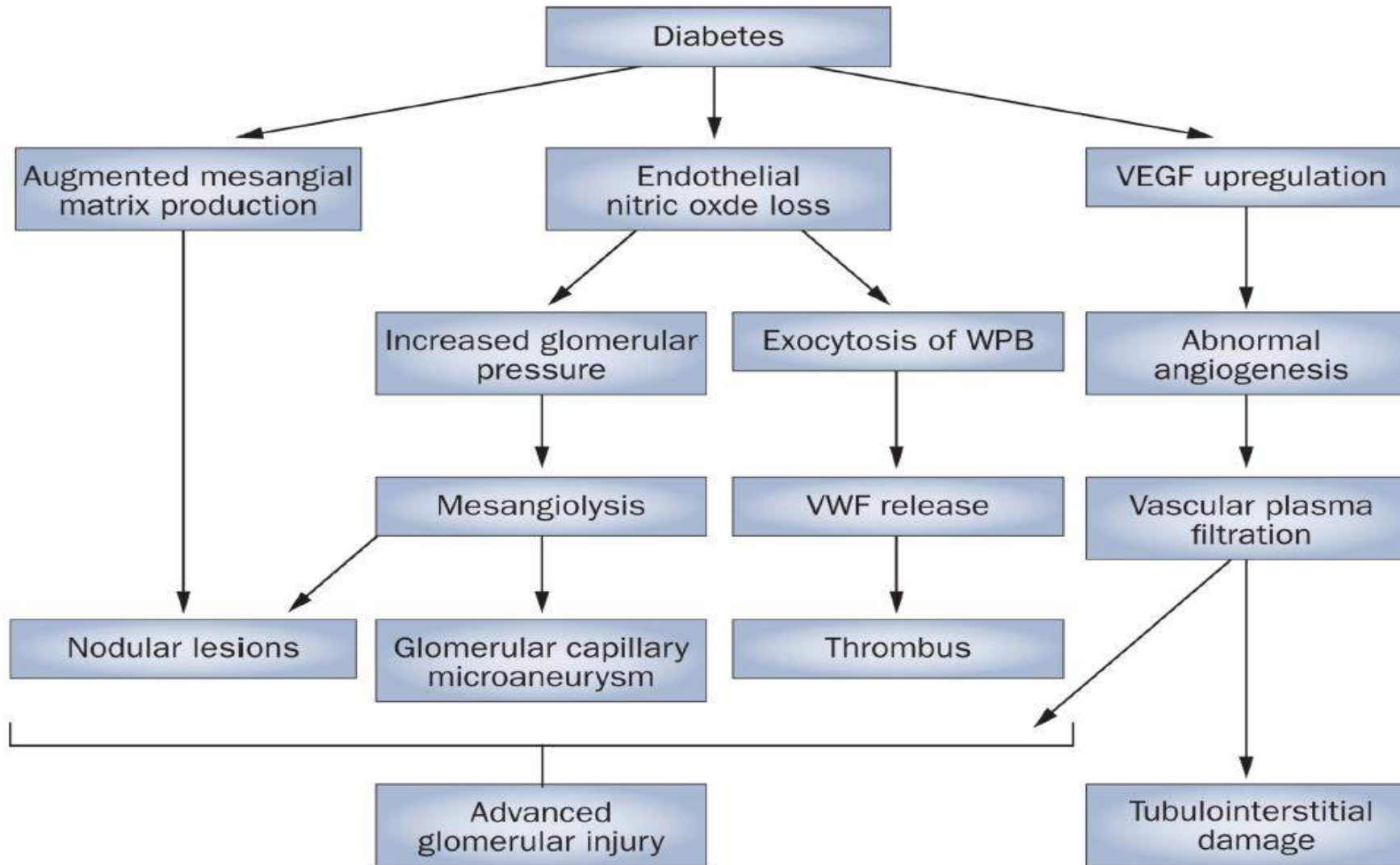
# Diyabetik Nefropati: Vasküler Endotelyel Growth Faktör



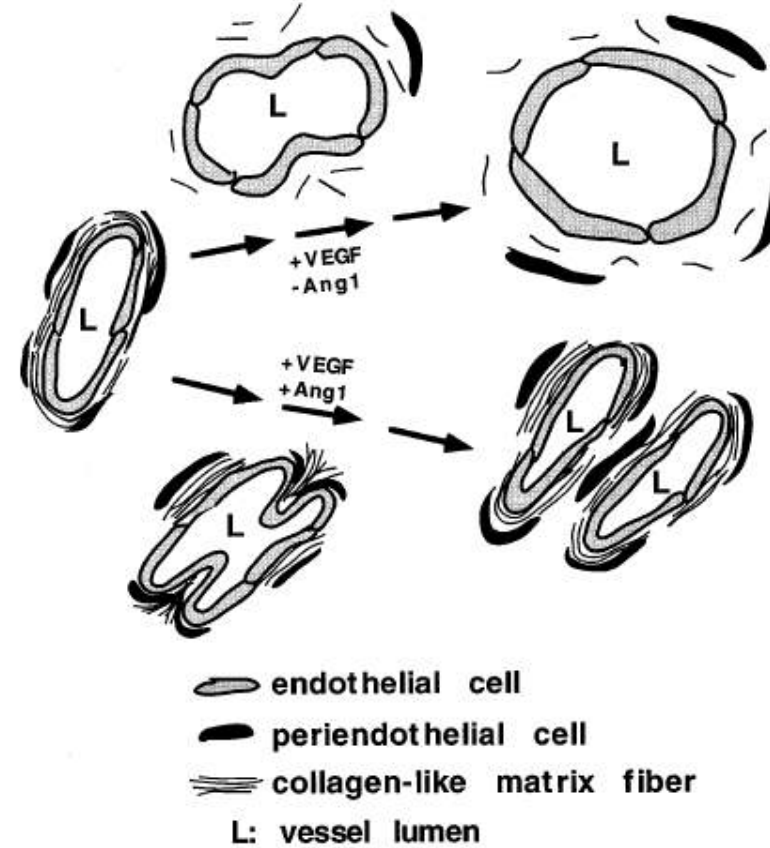
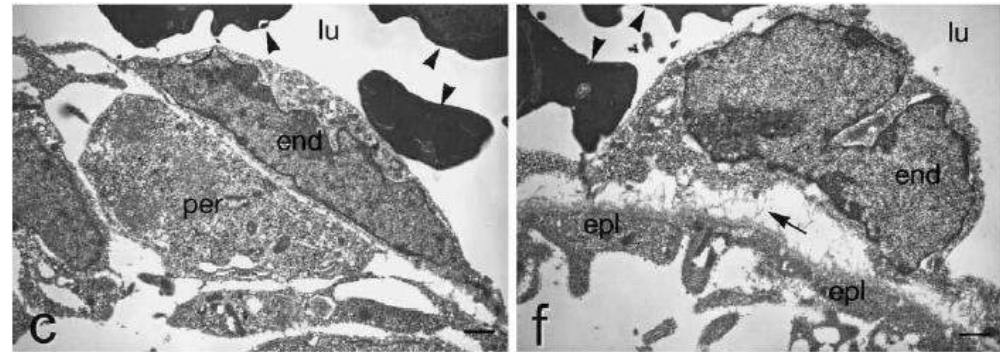
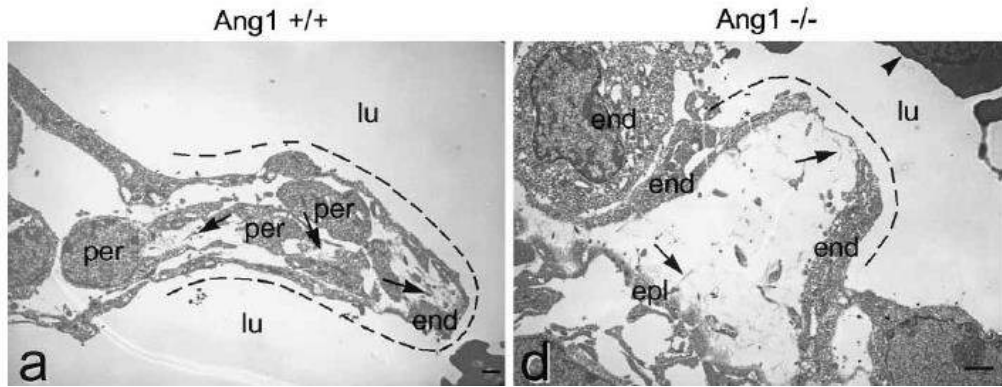
# Diyabetik Nefropati: Vasküler Endotelyel Growth Faktör



# Diyabetik Nefropati

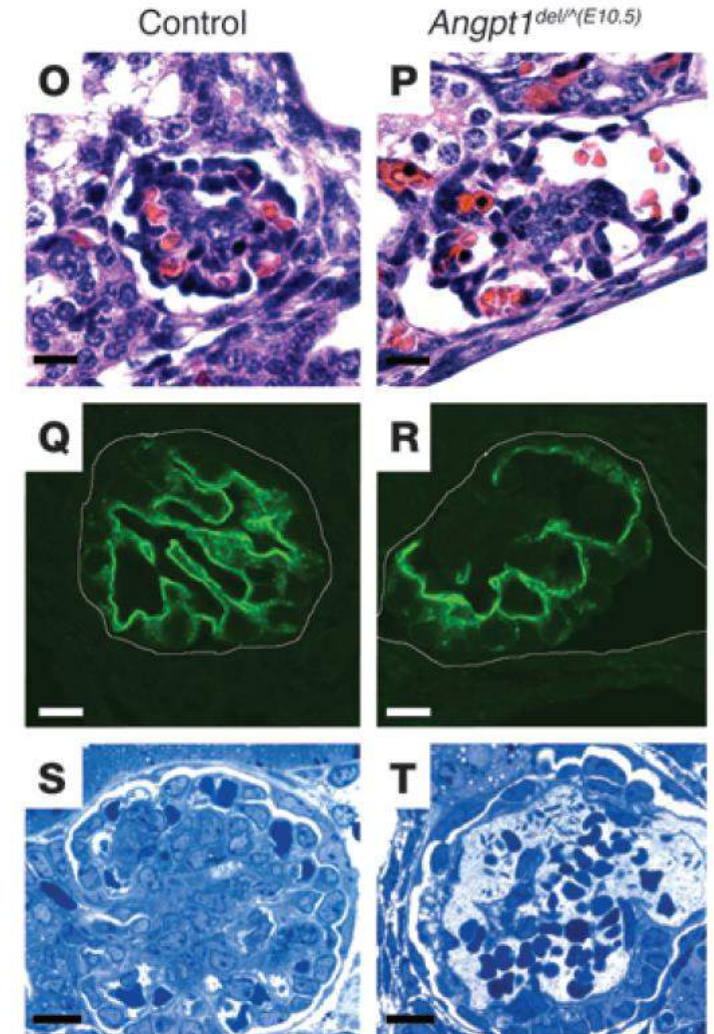
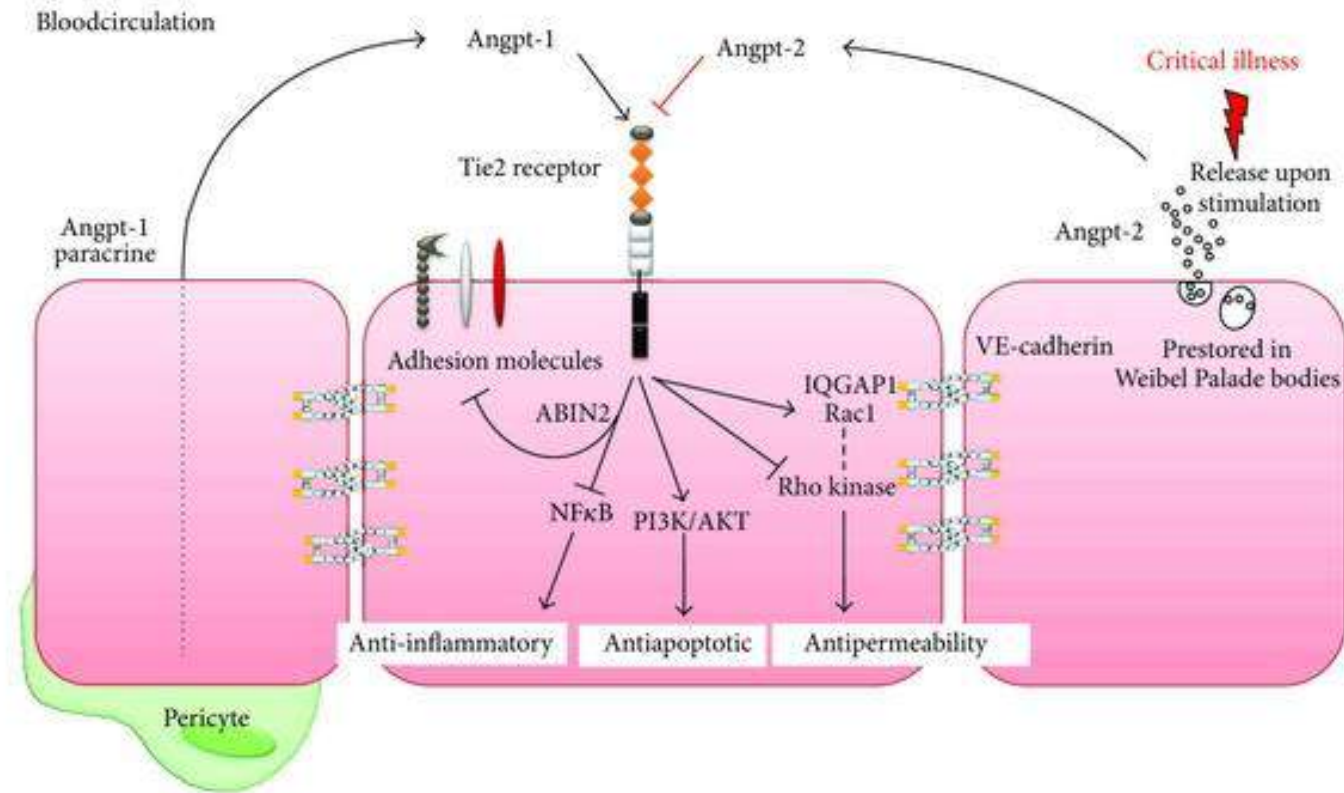


# Diyabetik Nefropati: Anjiopoeitinler

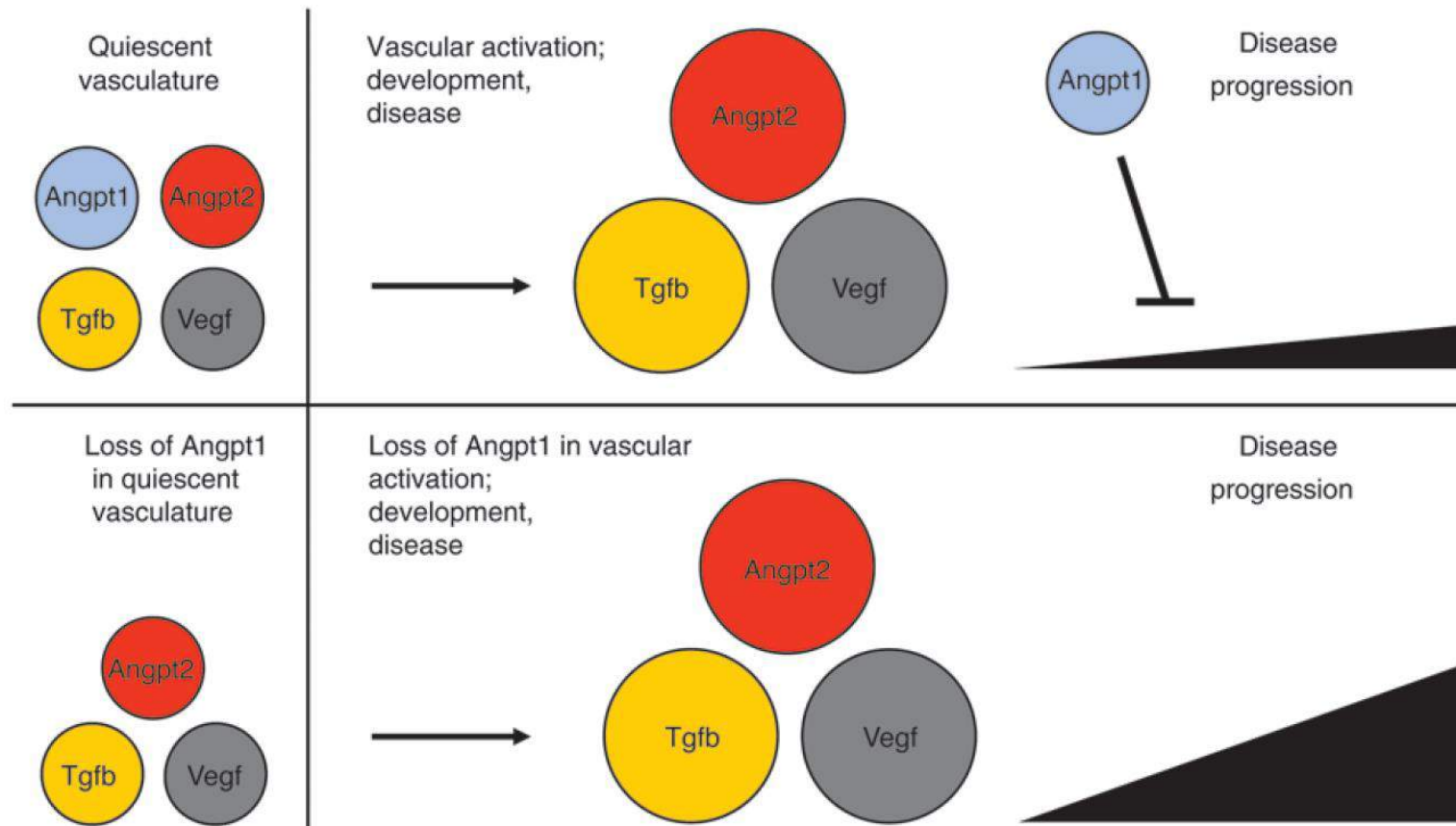




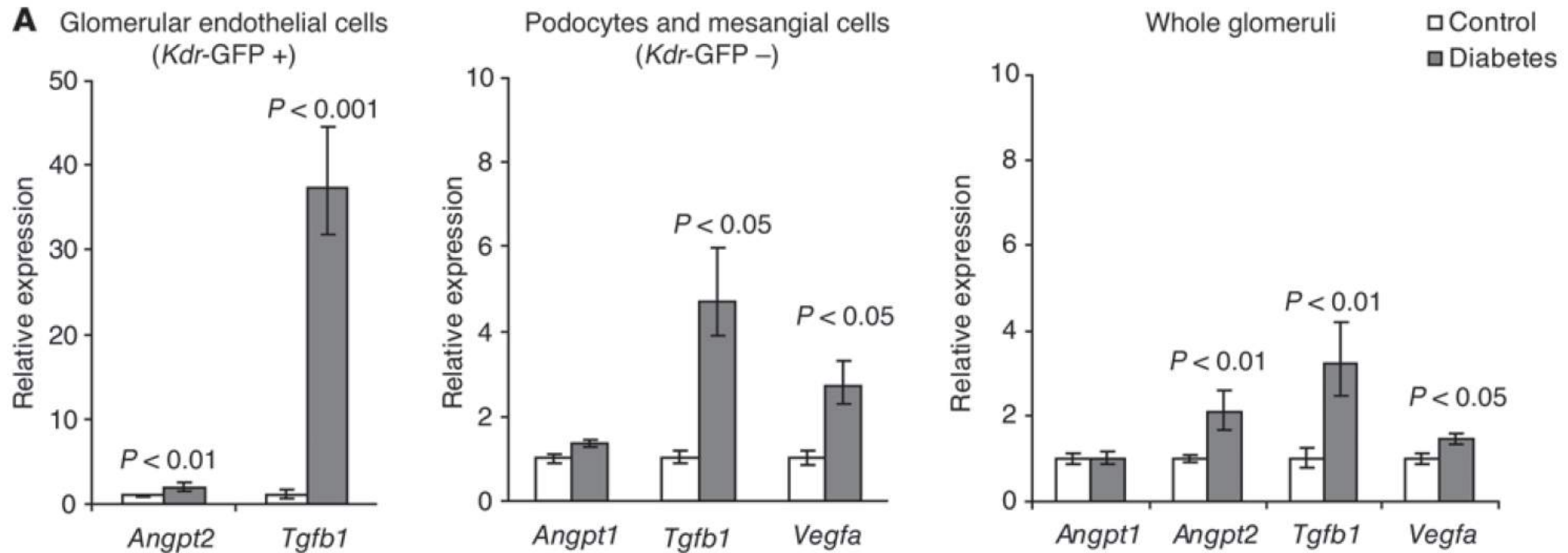
# Diyabetik Nefropati: Anjiopoeitinler



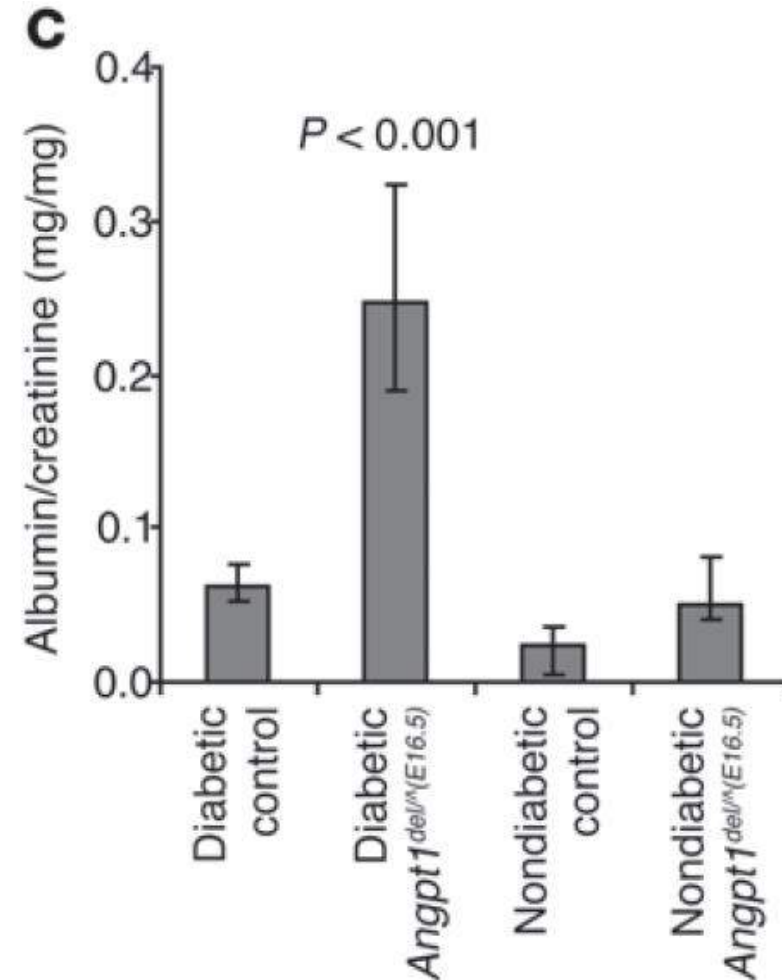
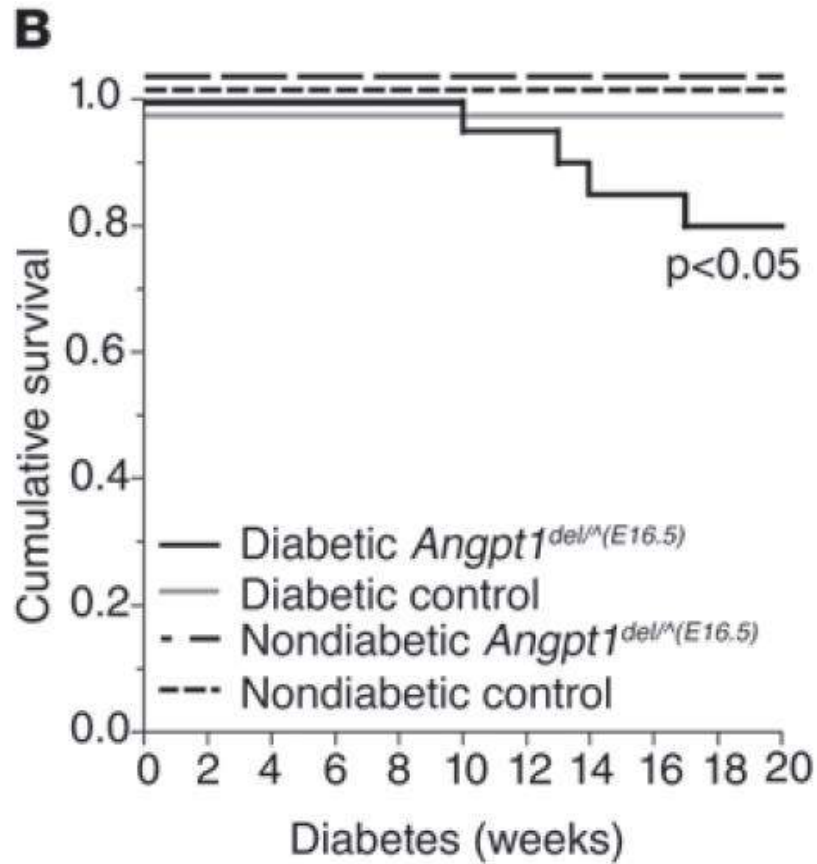
# Diyabetik Nefropati: Anjiopoeitinler



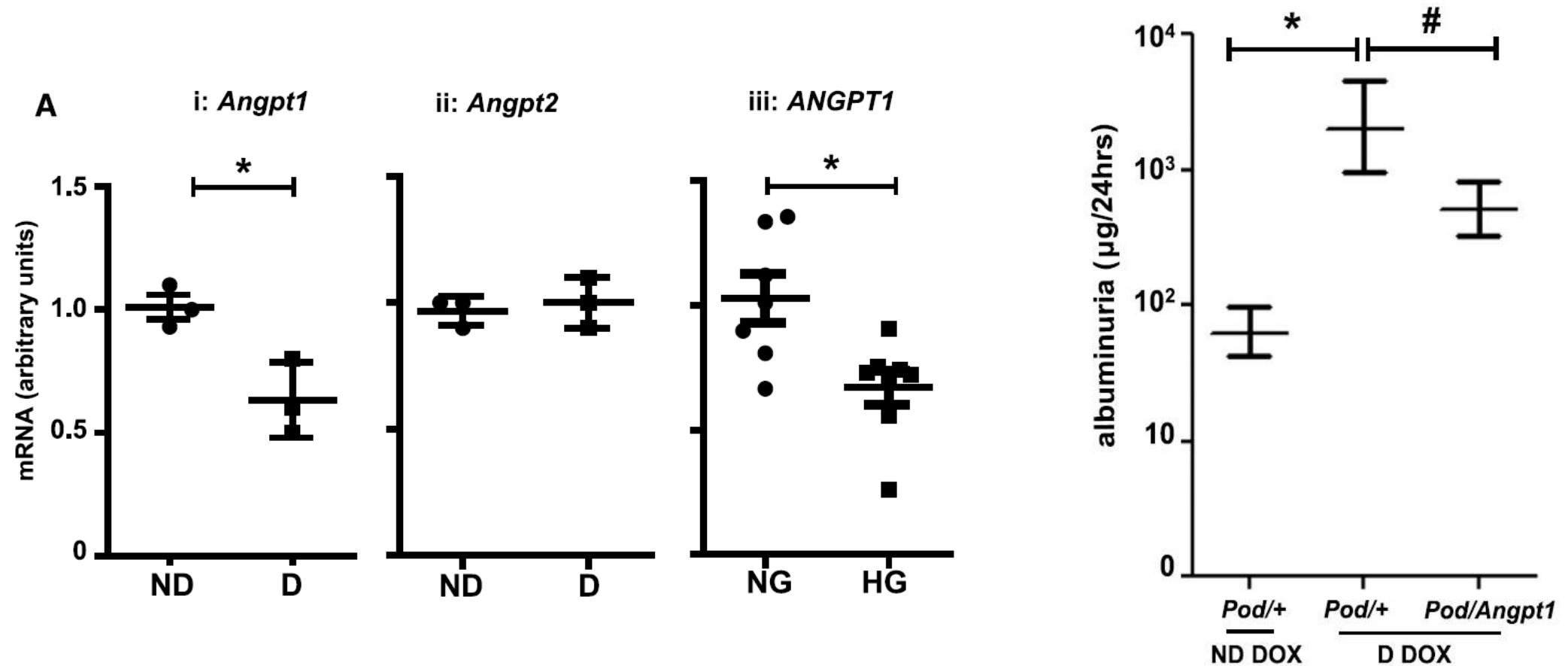
# Diyabetik Nefropati: Anjiopoeitinler



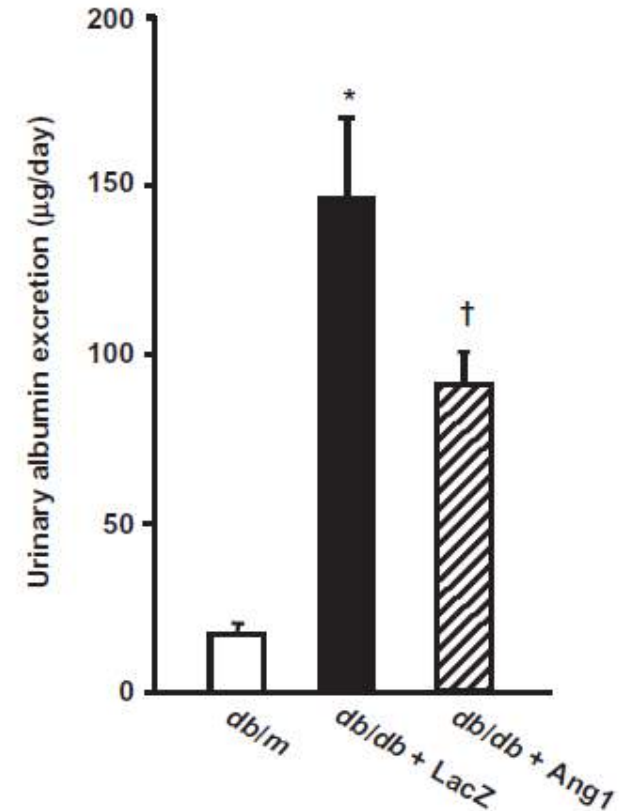
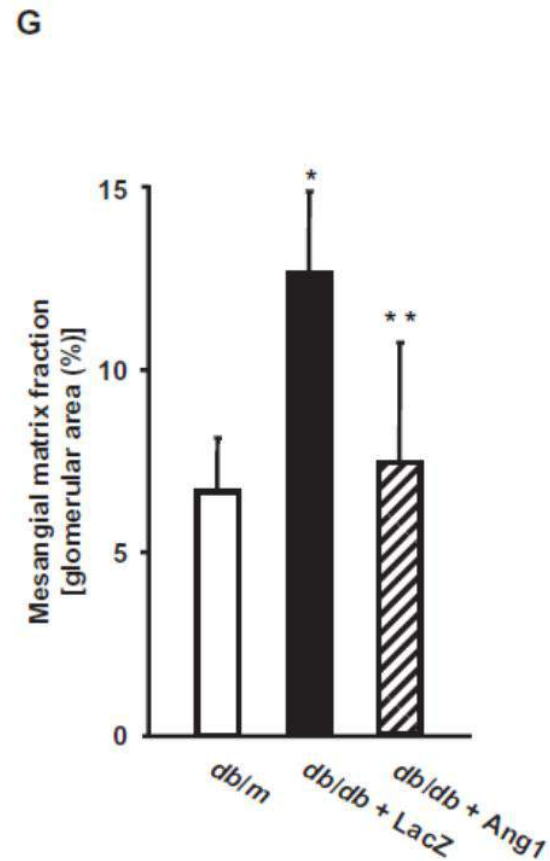
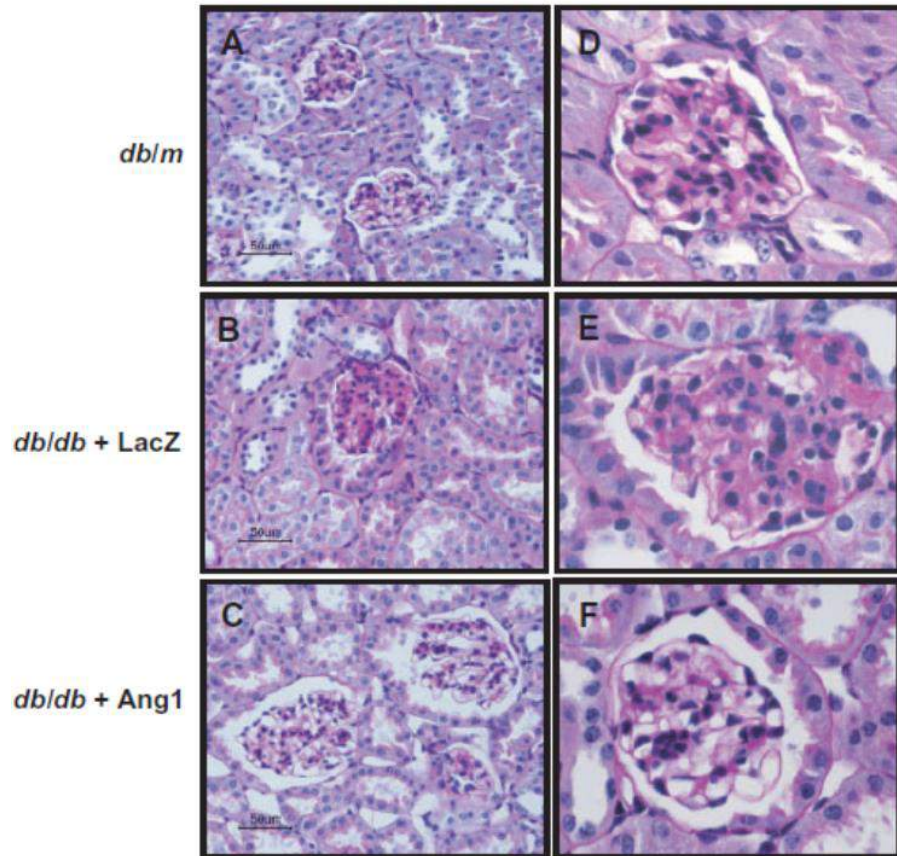
# Diyabetik Nefropati: Anjiopoeitinler



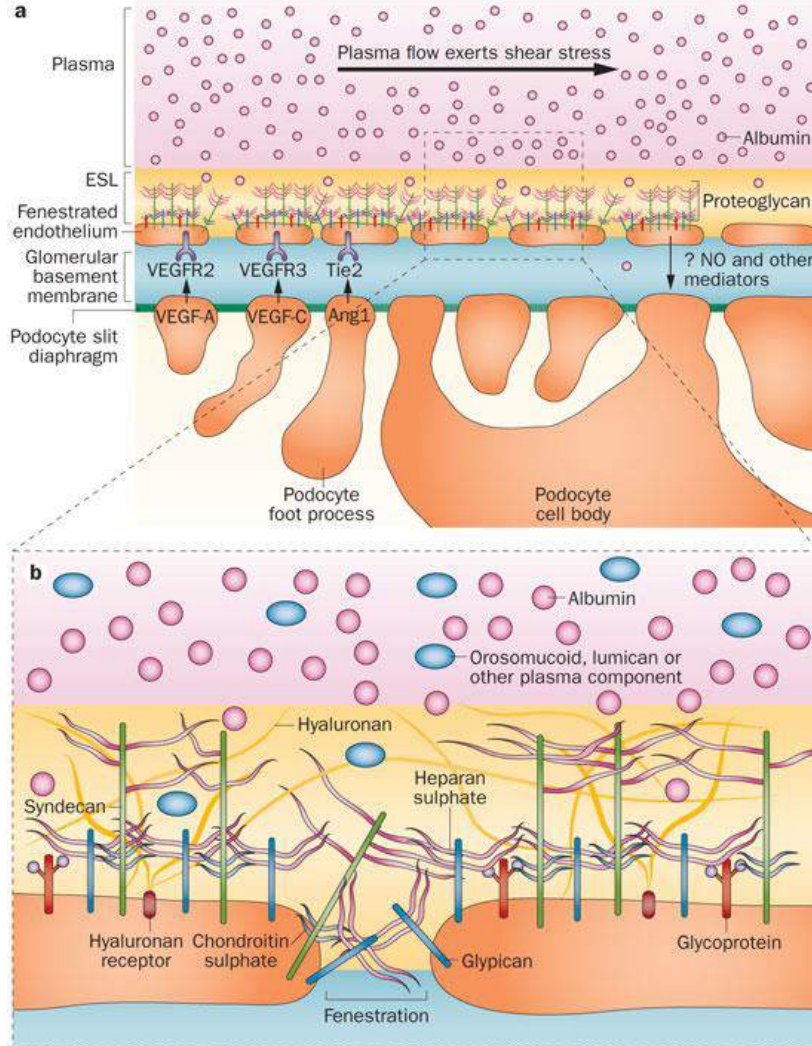
# Diyabetik Nefropati: Anjiopoeitinler



# Diyabetik Nefropati: Anjiopoeitinler



# Diyabetik Nefropati: Glomerüler Endotel Hücreleri



GLİKOKALIKSDE AZALMA

ENDOTEL FENESTRASYONUNDA AZALMA

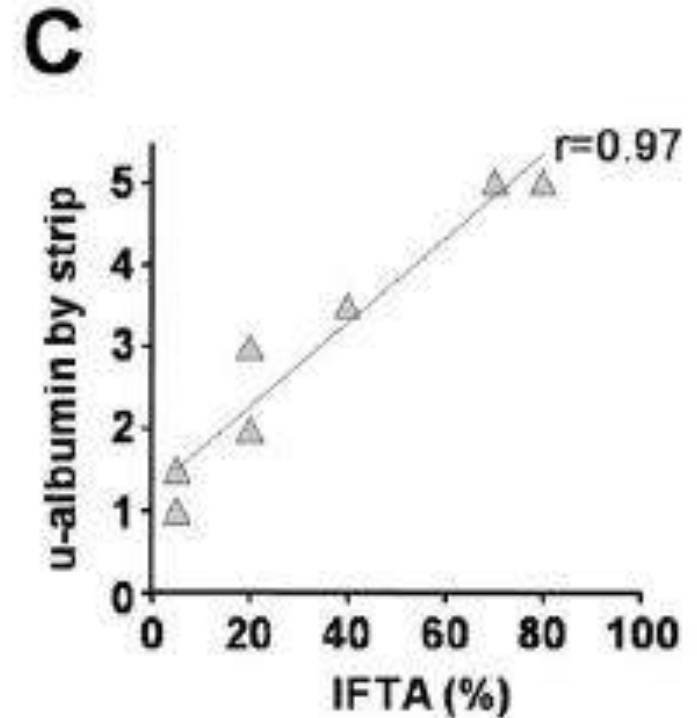
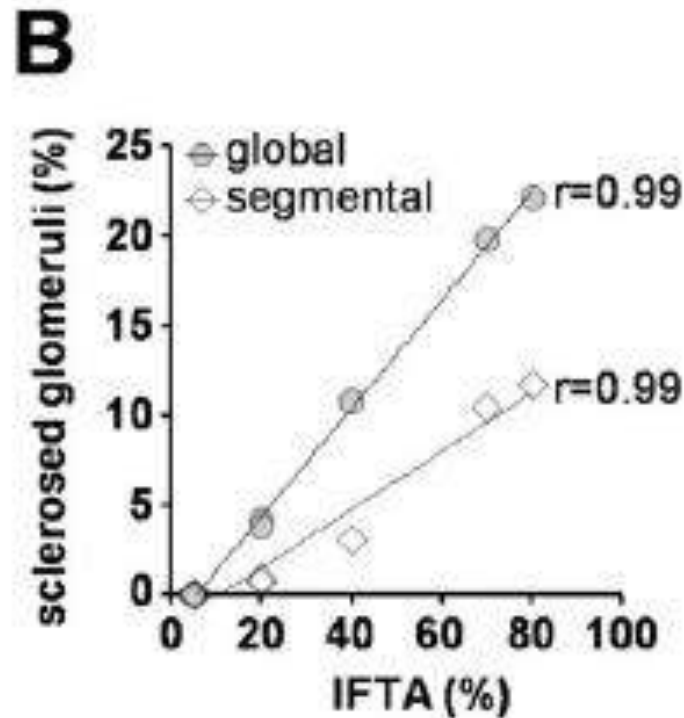
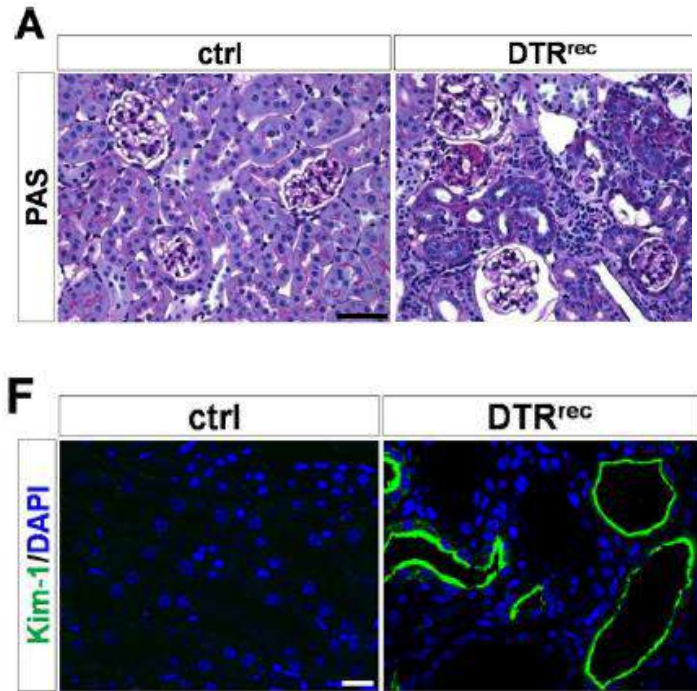
VEFG/ENOS DENGESİNDE BOZULMA

NO ÜRETİMİNDE AZALMA

SUPEROKSİT ÜRETİMİNDE ARTIŞ

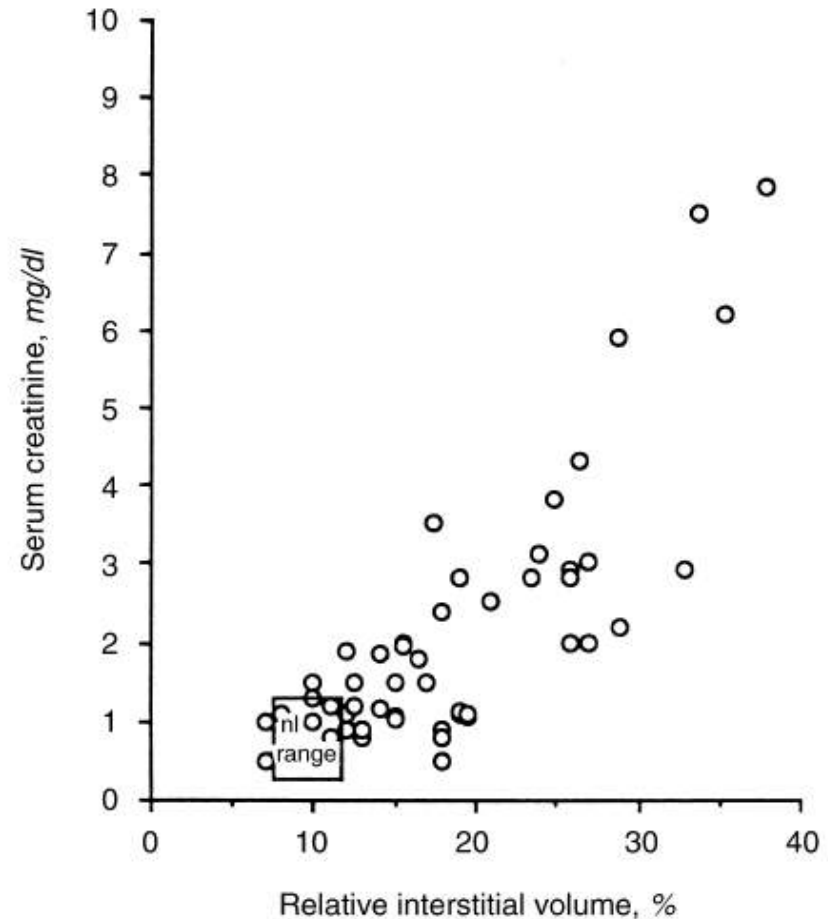
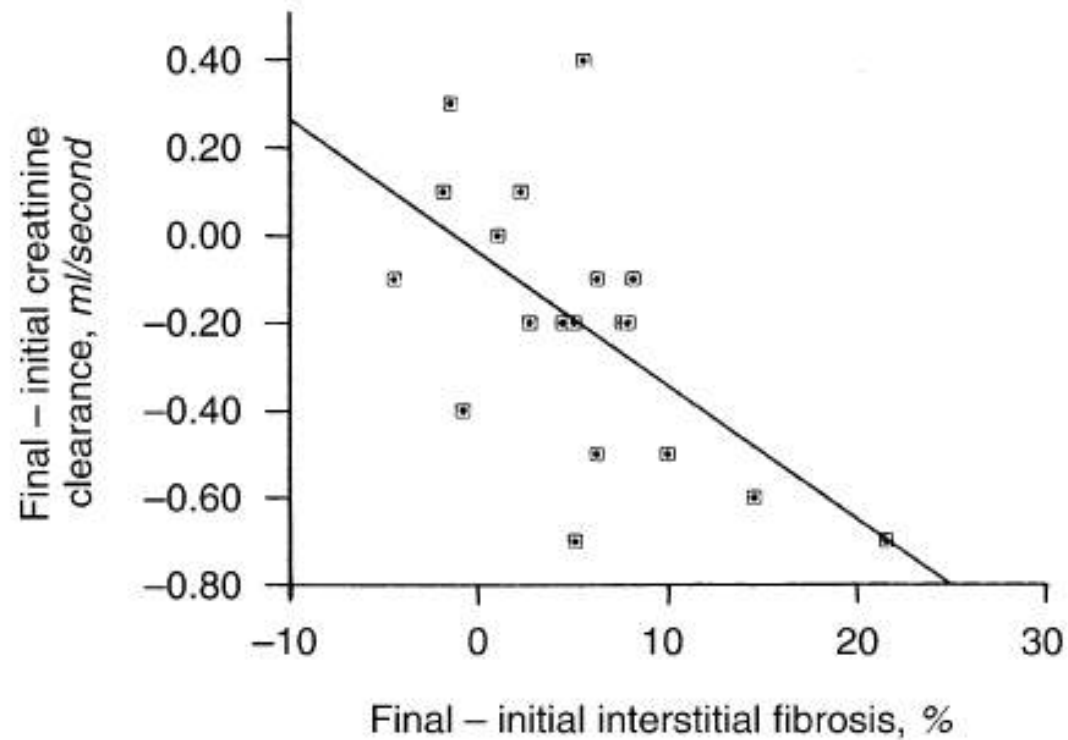
ANJİOPOETİN 1 / 2 DENGESİNDE  
BOZULMA

# Diyabetik Nefropati: Tübulointerstisyel Hücreler

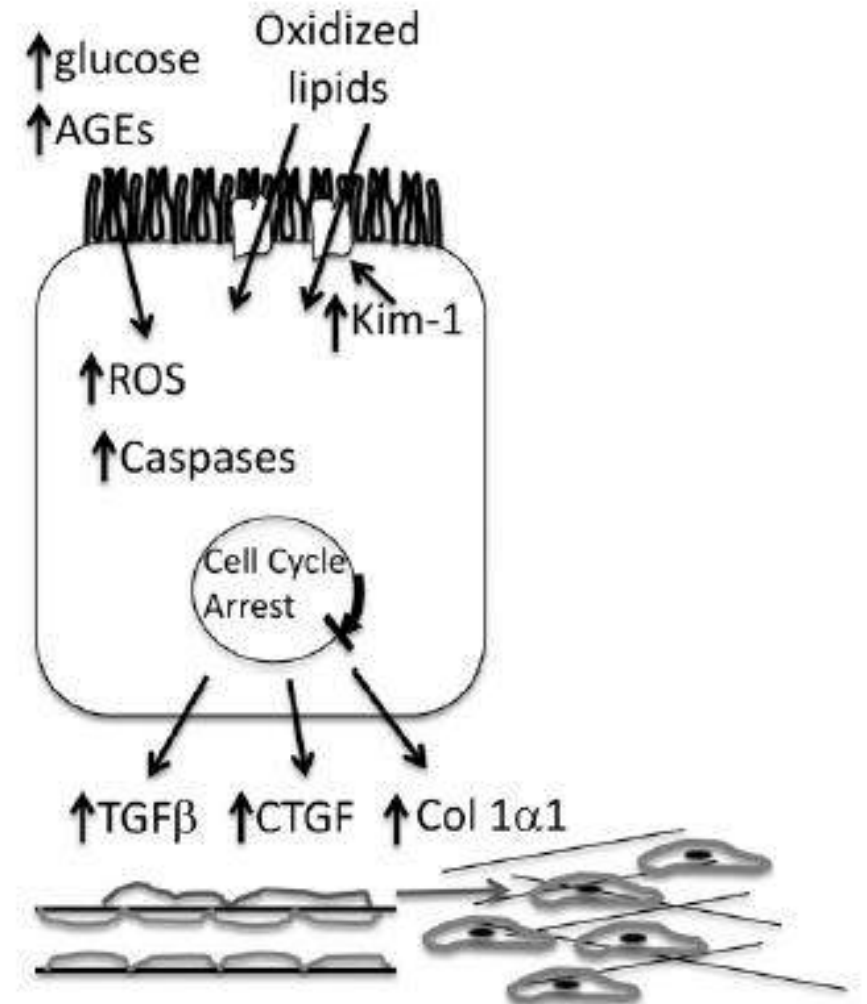
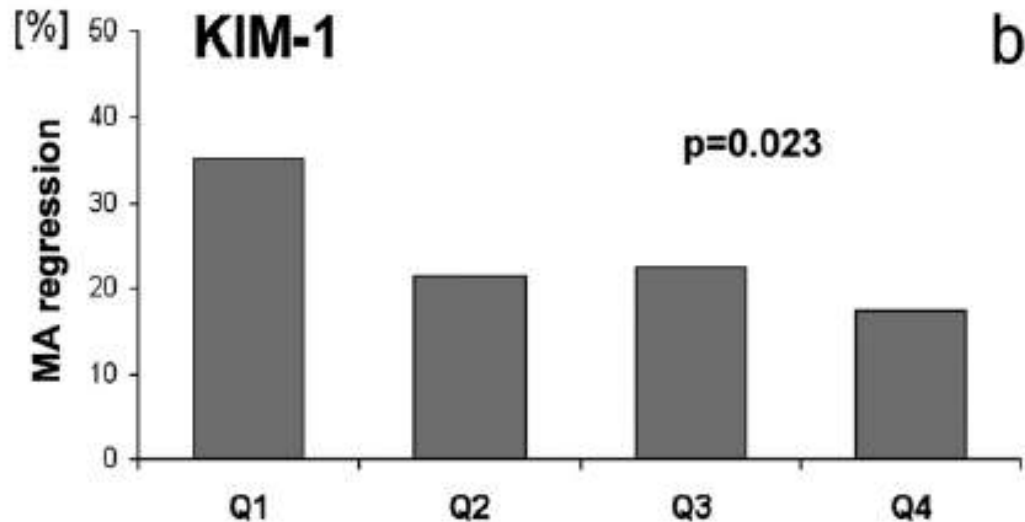
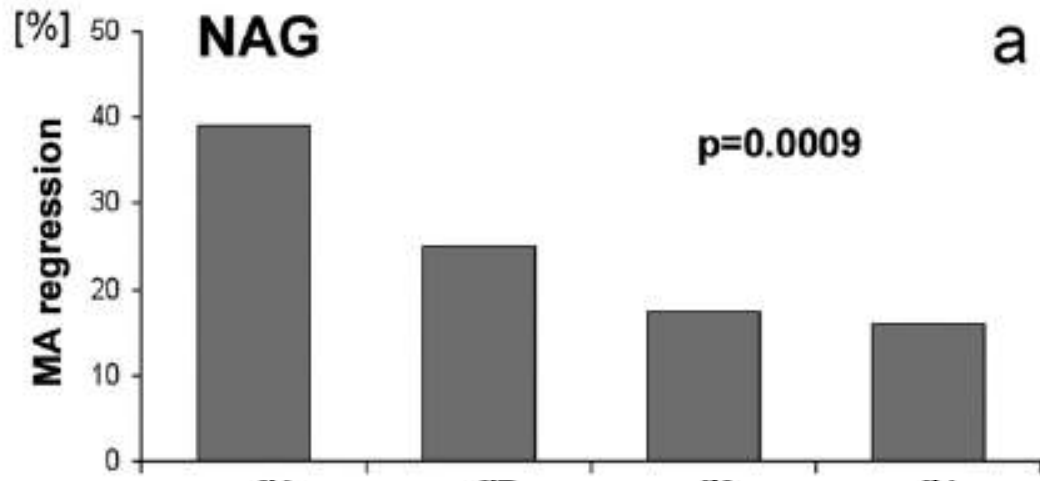




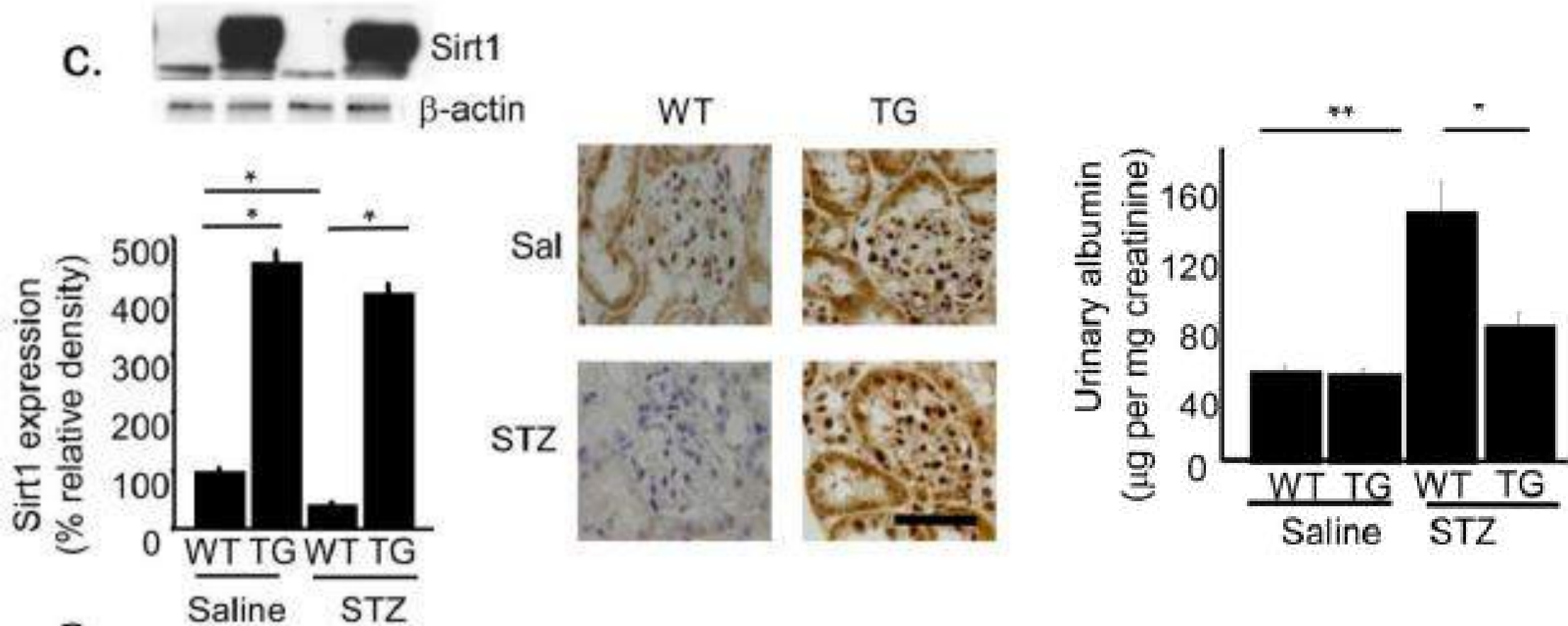
# Diyabetik Nefropati: Tübulointerstisyel Hücreler



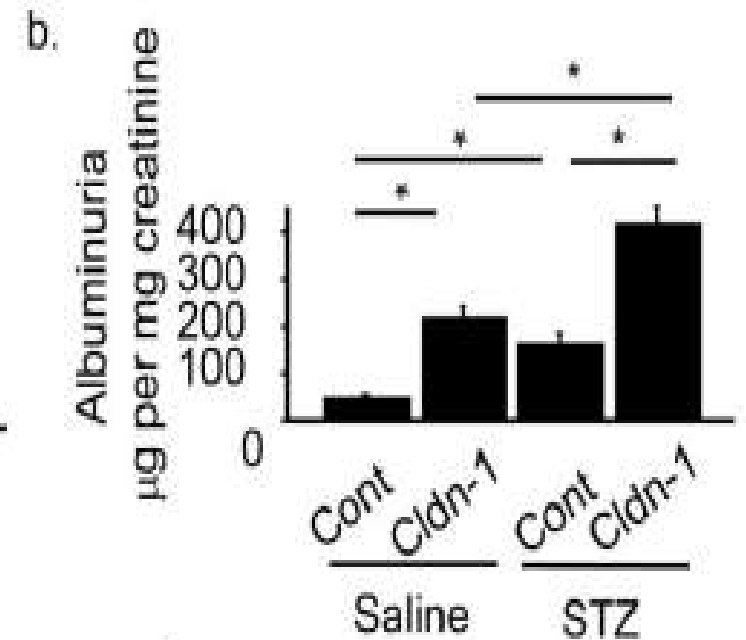
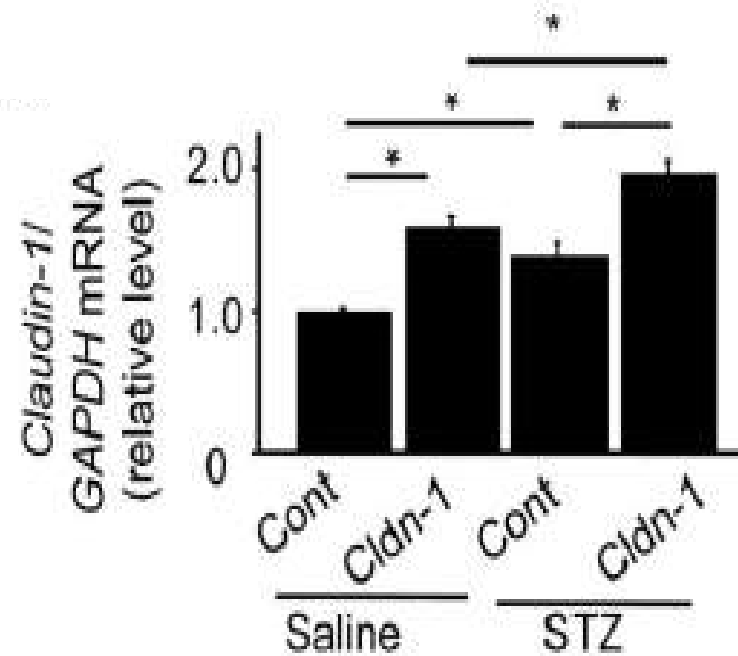
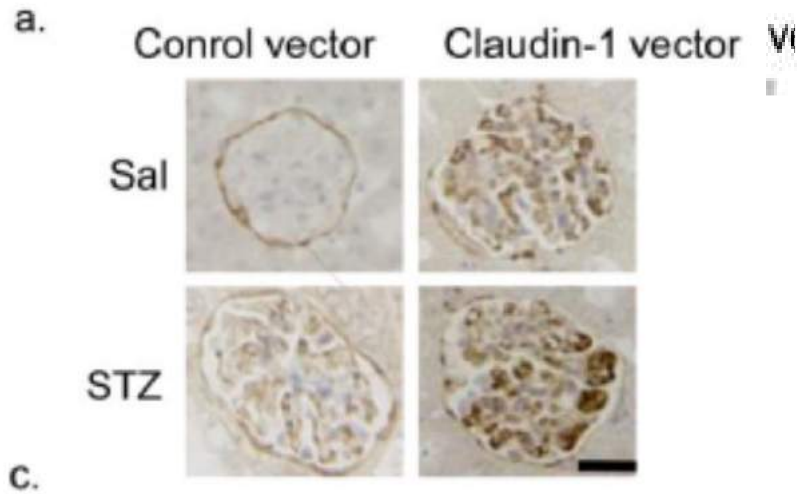
# Diyabetik Nefropati: Tübulointerstisyel Hücreler



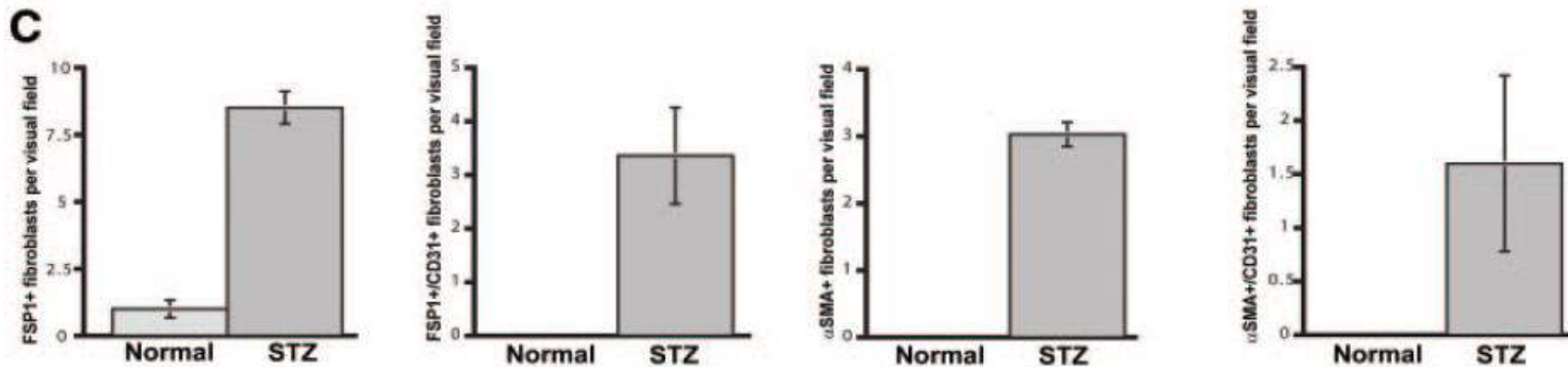
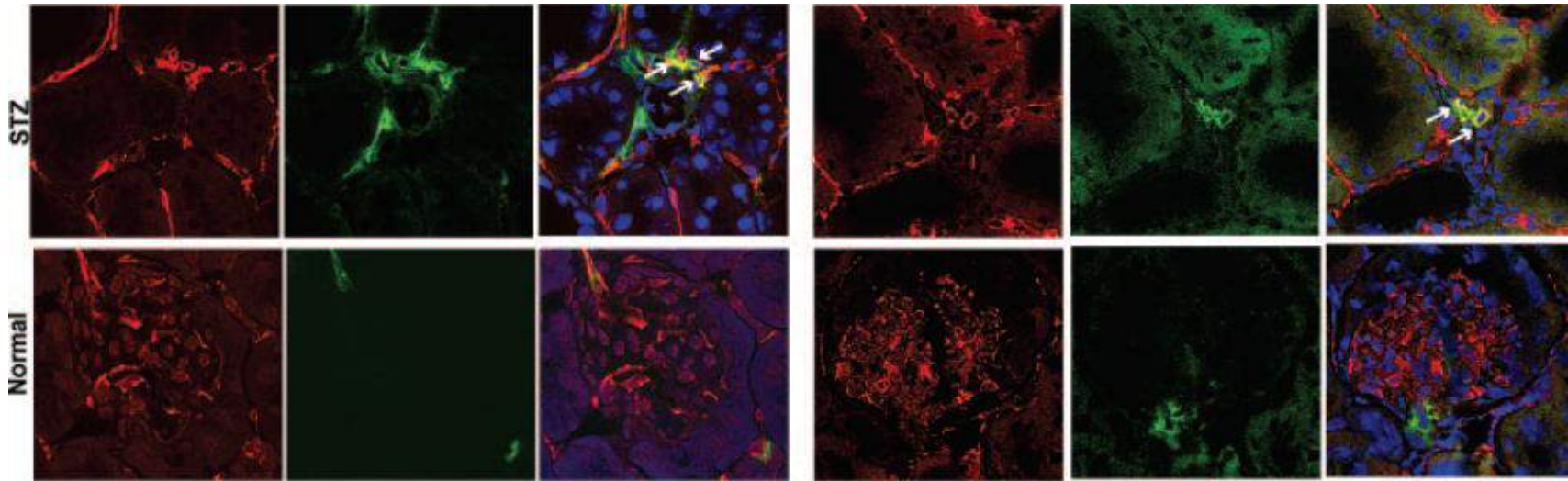
# Diyabetik Nefropati: Tübulointerstisyel Hücreler



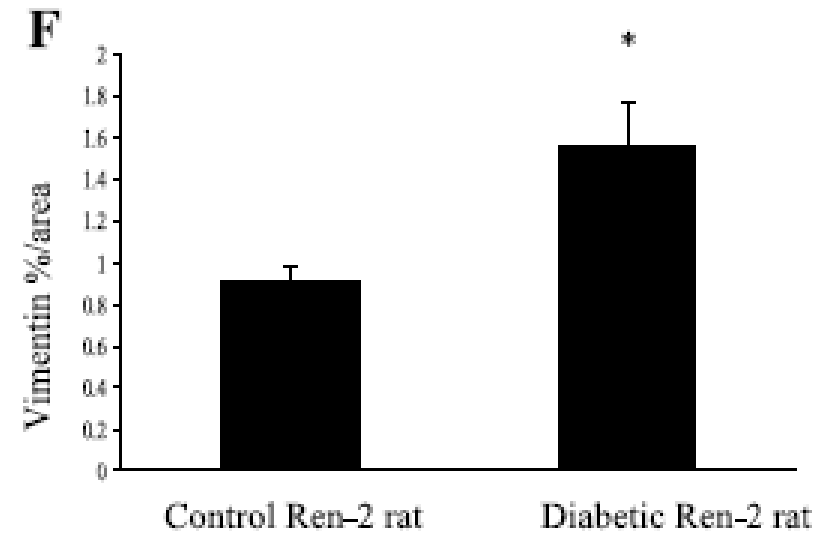
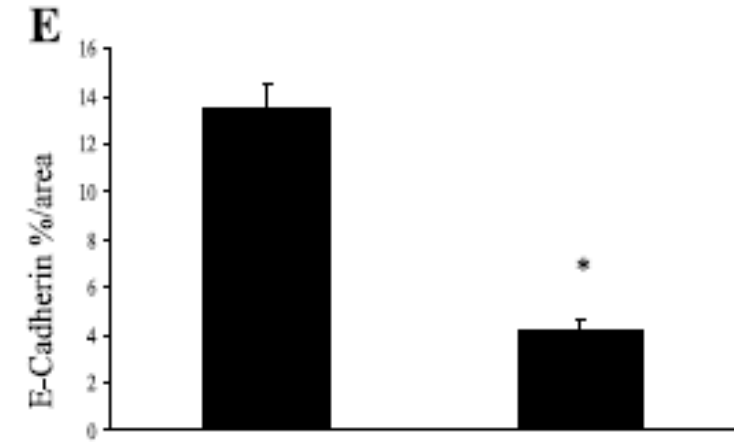
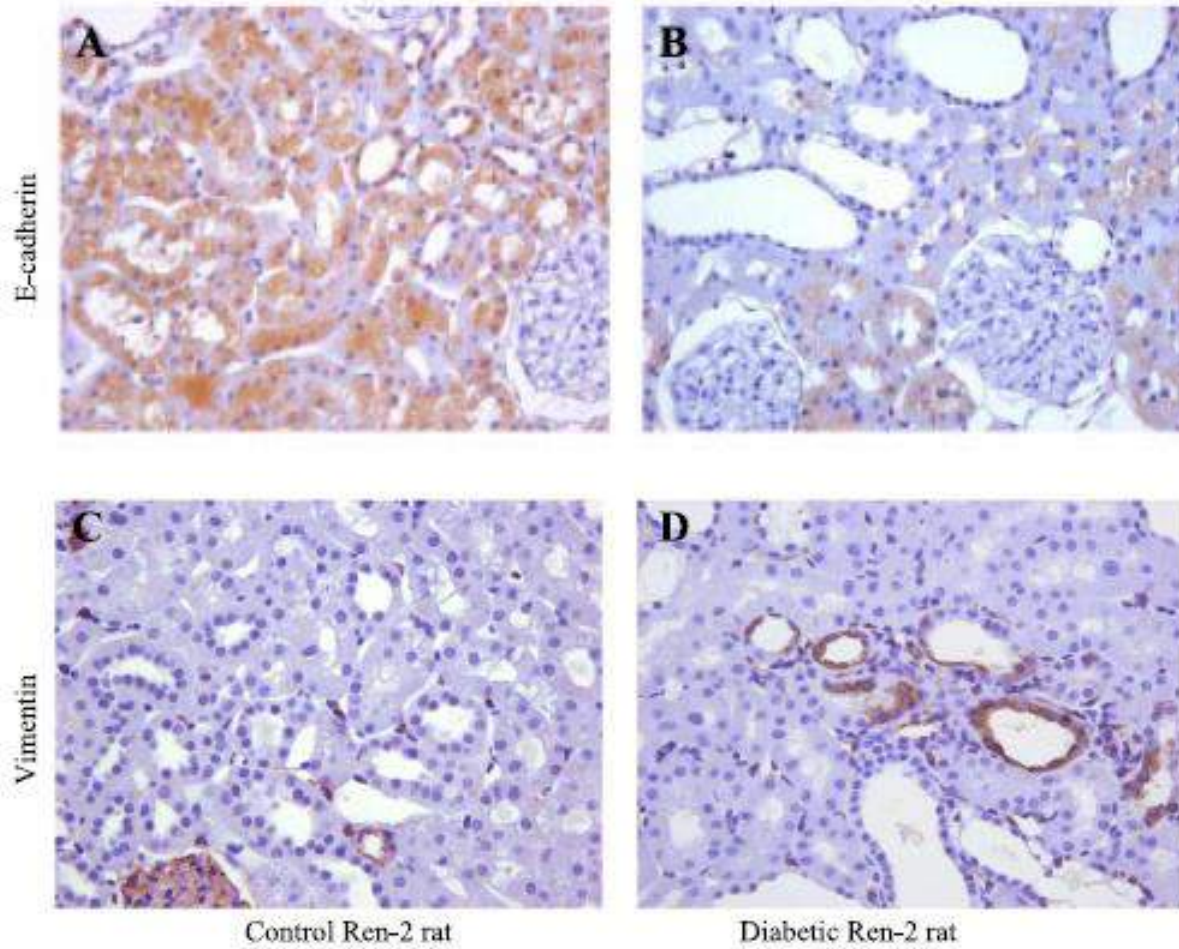
# Diyabetik Nefropati: Tübulointerstisyel Hücreler



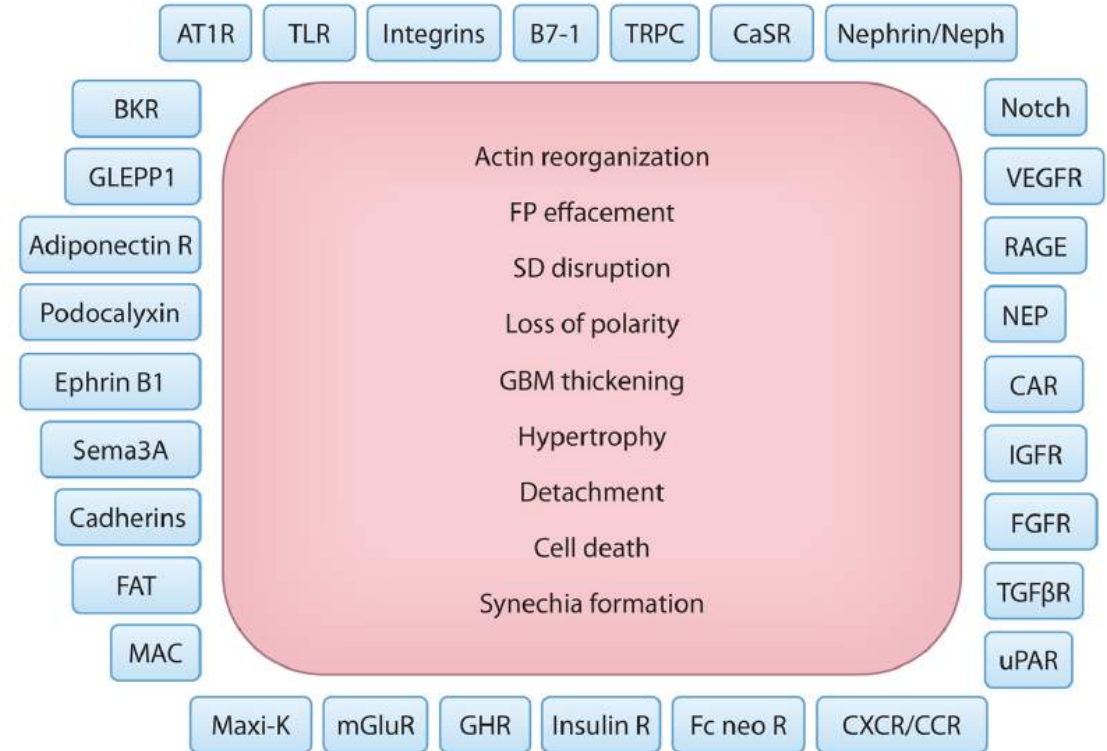
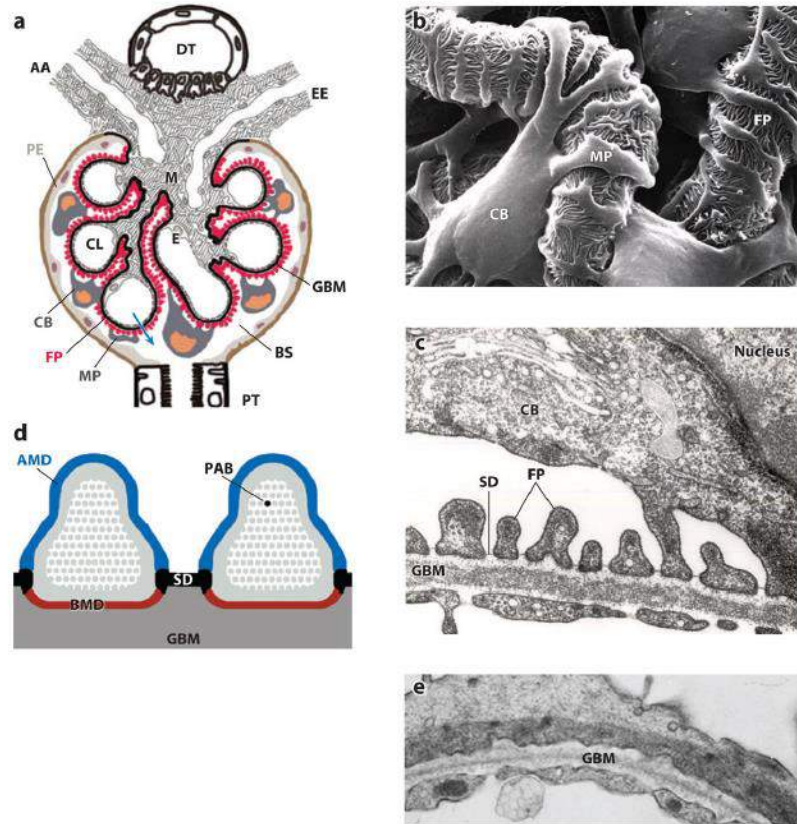
# Diyabetik Nefropati: Tübulointerstisyel Hücreler



# Diyabetik Nefropati: Tübulointerstisyel Hücreler

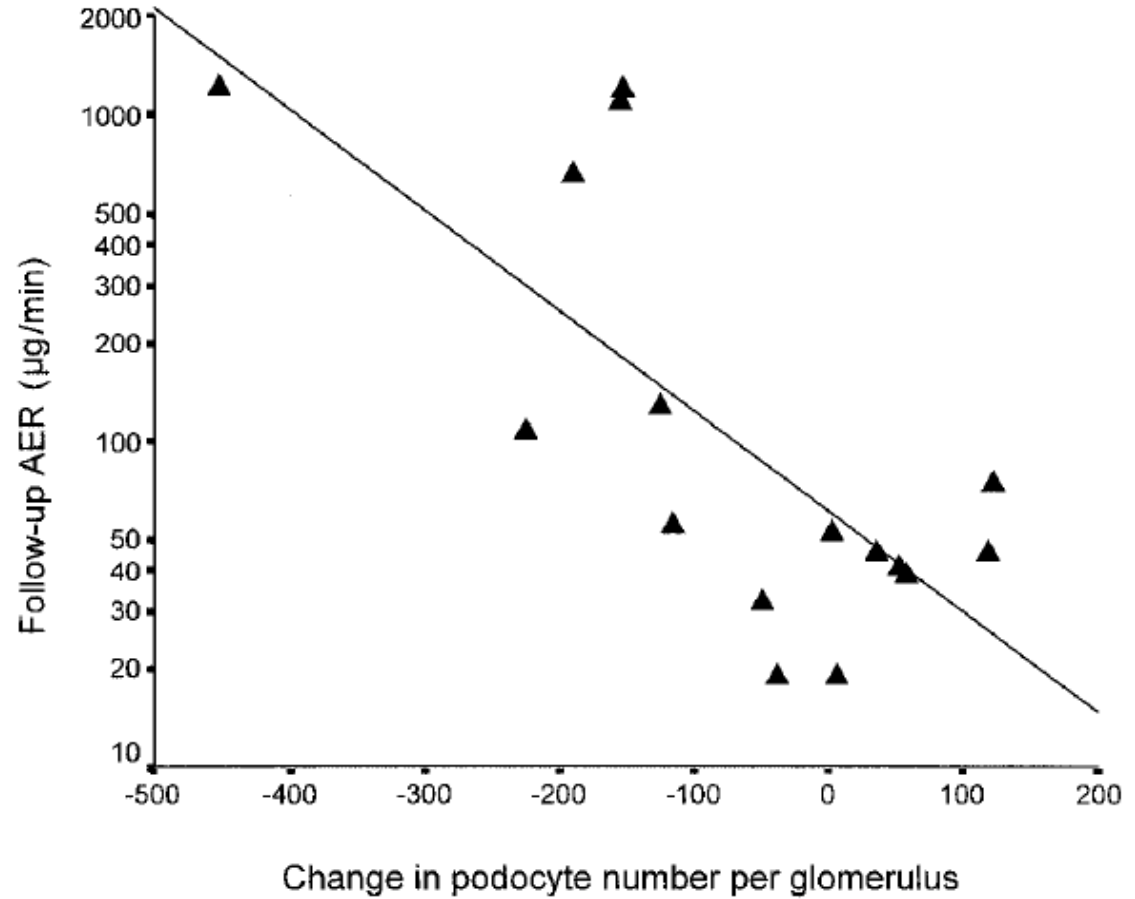
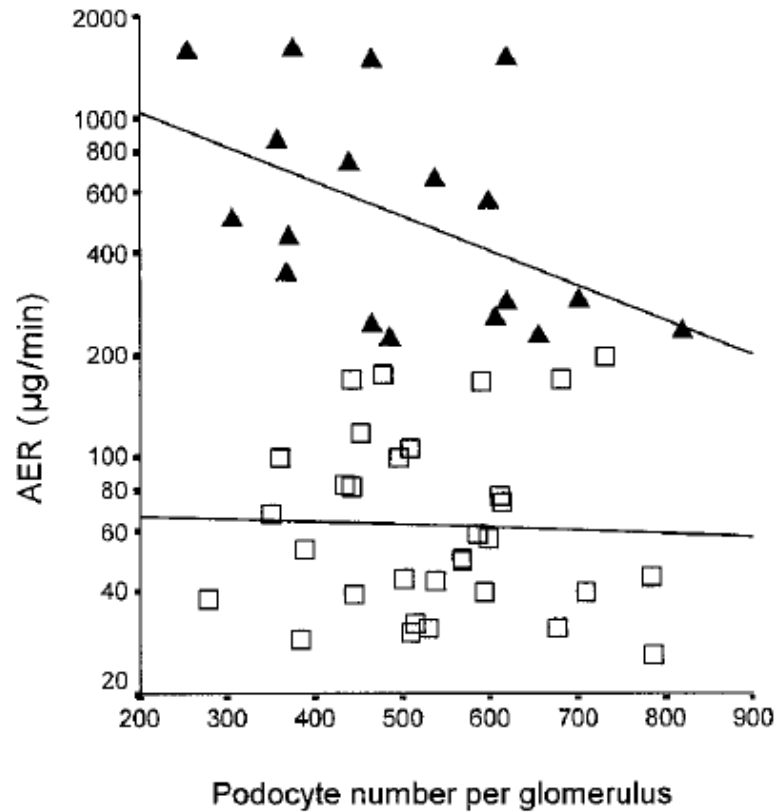


# Diyabetik Nefropati: Podositler



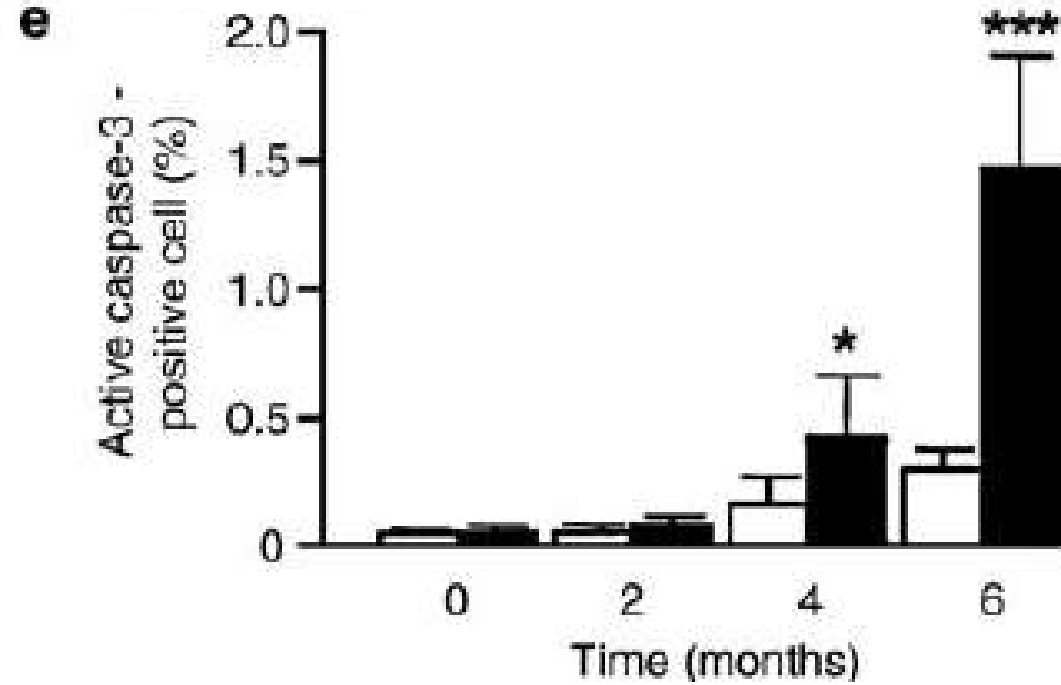
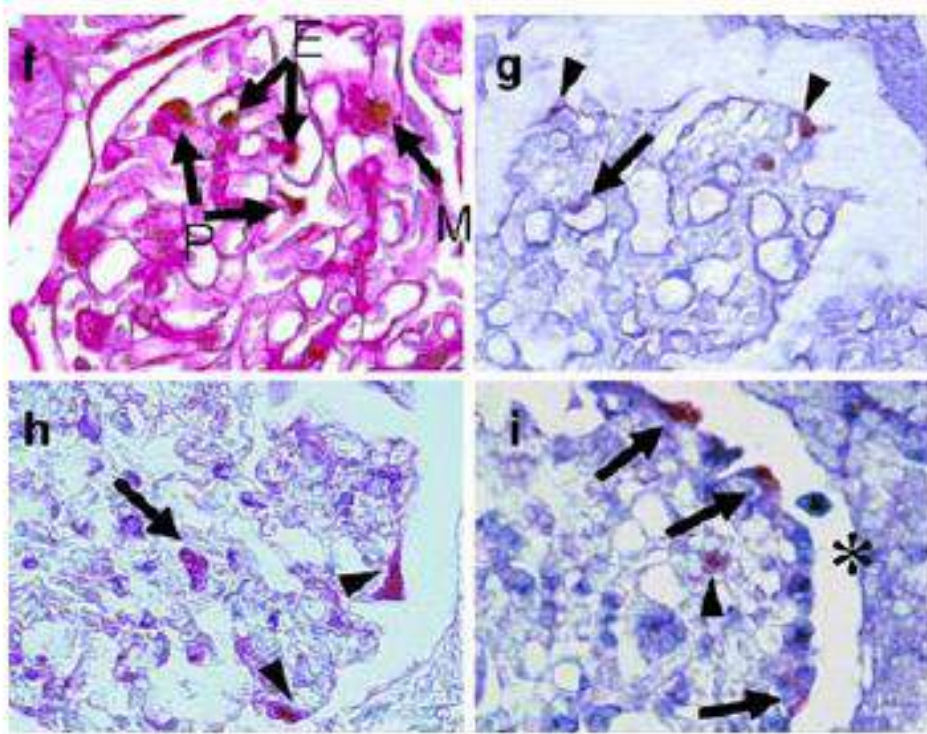
# Diyabetik Nefropati: Podositler

**B**

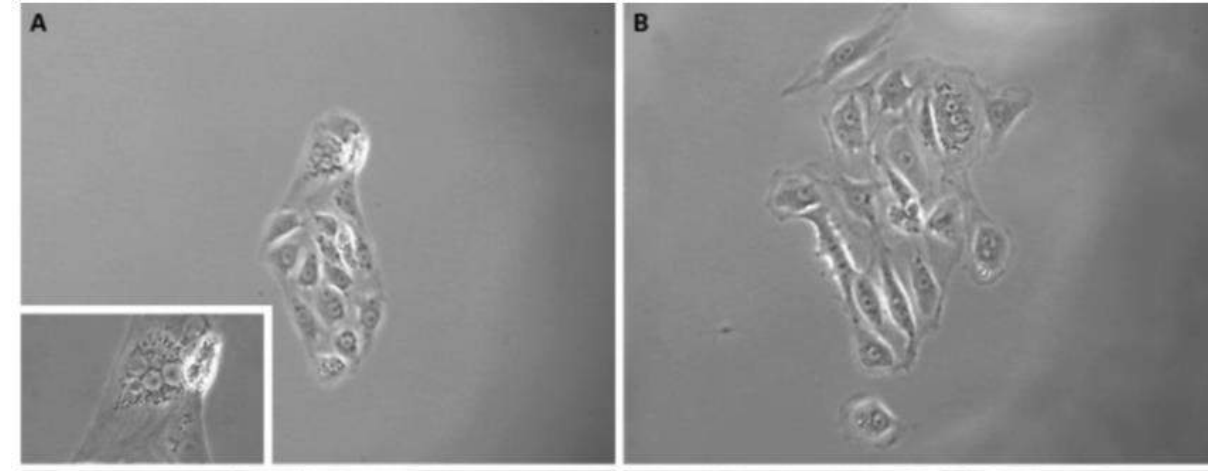
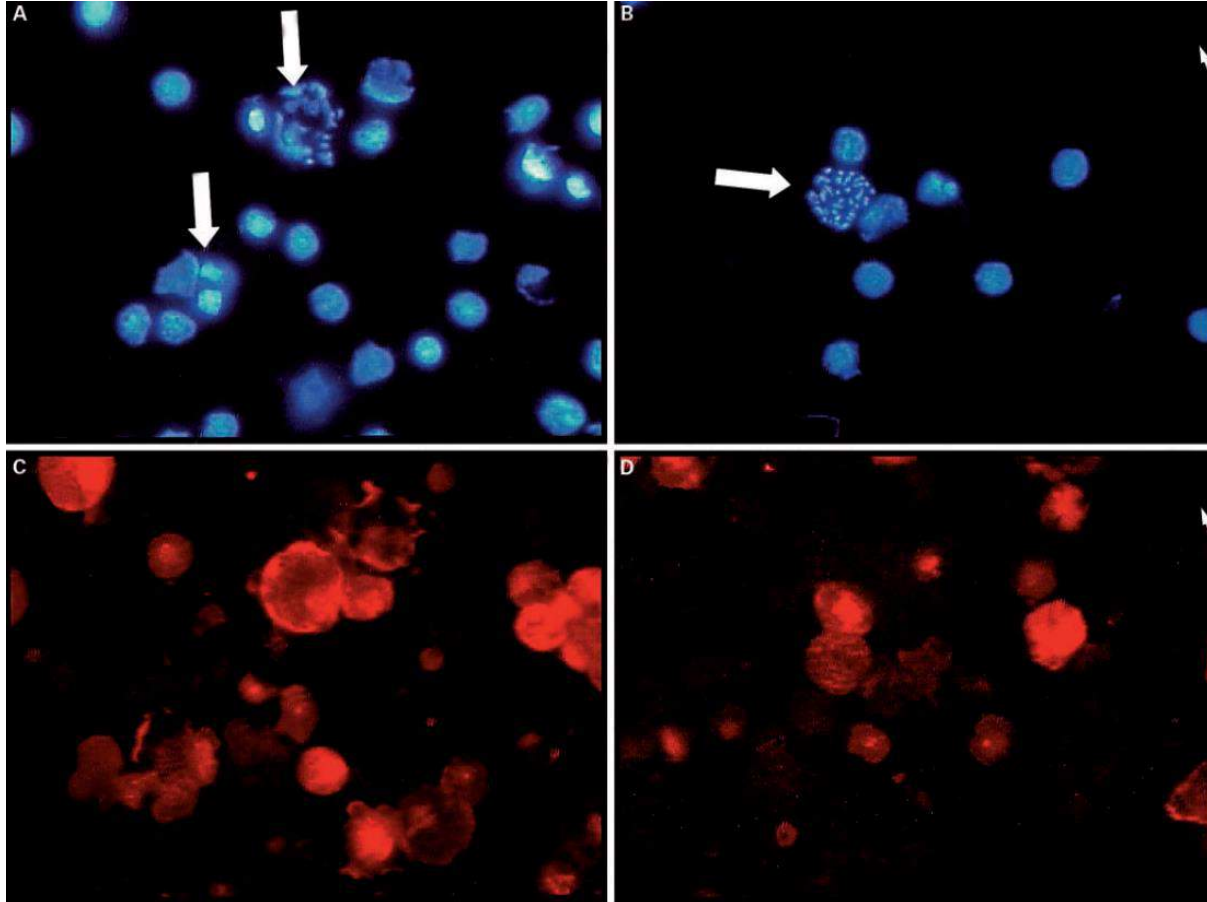




# Diyabetik Nefropati: Podosit Hasarı



# Diyabetik Nefropati: Podosit Hasarı



# Diyabetik Nefropati: Podosit Hasarı

**Advanced glycation endproducts induce podocyte apoptosis by activation of the FOXO4 transcription factor**

PY Chuang<sup>1</sup>, Q Yu<sup>1</sup>, W Fang<sup>1</sup>, J Uribarri<sup>1</sup>, and JC He<sup>1</sup>

<sup>1</sup>Division of Nephrology, Department of Medicine, Mount Sinai School of Medicine and James J Peters VA Medical Center, New York, New York, USA

## **Angiotensin II Infusion Induces Nephryn Expression Changes and Podocyte Apoptosis**

no86

Junya Jia<sup>a</sup> Guohua Ding<sup>a</sup> Jili Zhu<sup>a</sup> Cheng Chen<sup>a</sup> Wei Liang<sup>a</sup>  
Nicholas Franki<sup>b</sup> Pravin C. Singhal<sup>b</sup>

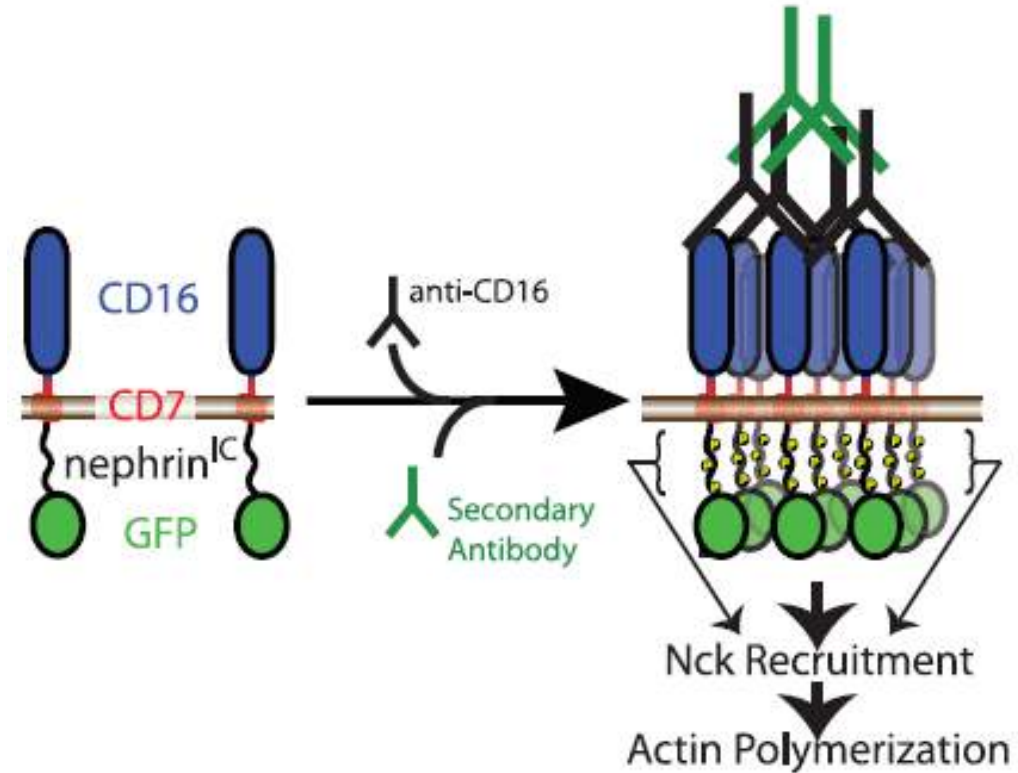
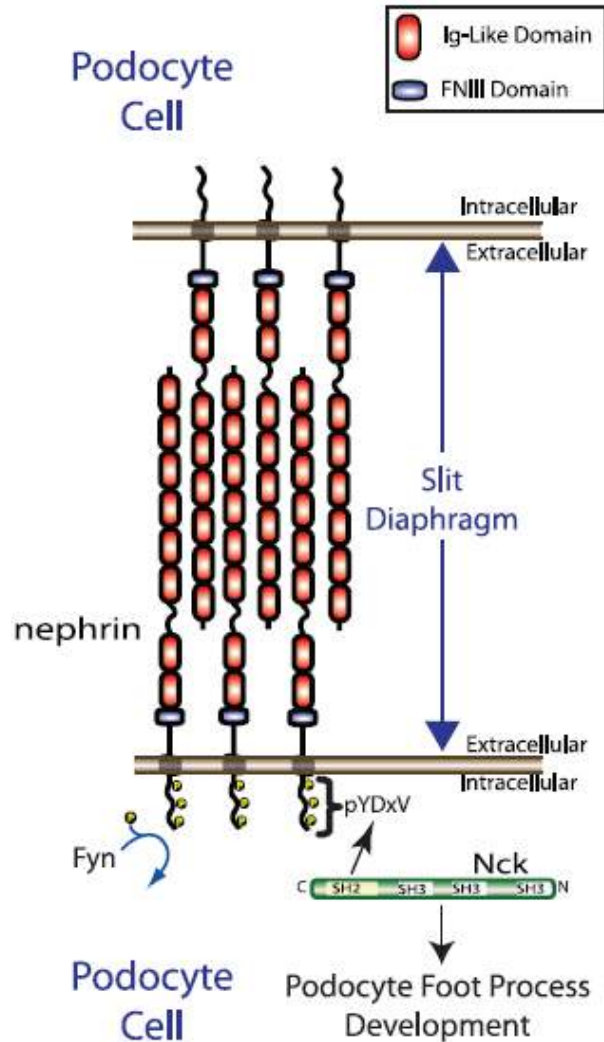
<sup>a</sup>Division of Nephrology, Renmin Hospital, Wuhan University, Wuhan, China; <sup>b</sup>Department of Medicine, Long Island Jewish Medical Center, New Hyde Park, N.Y., USA

## *Original Article*

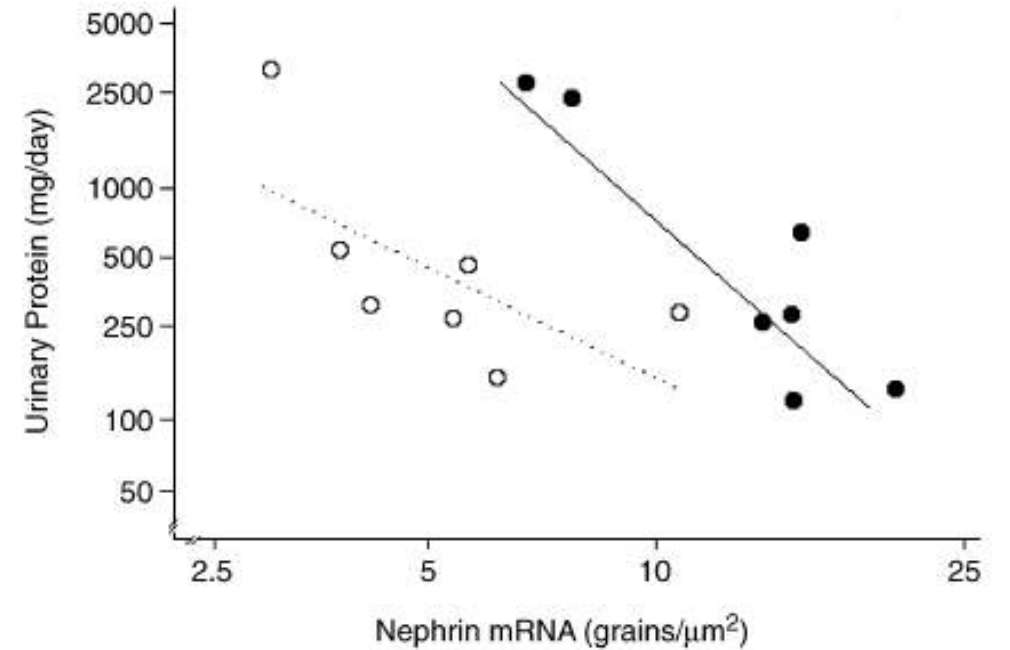
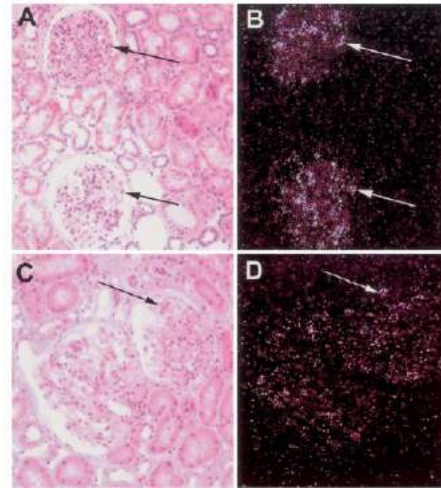
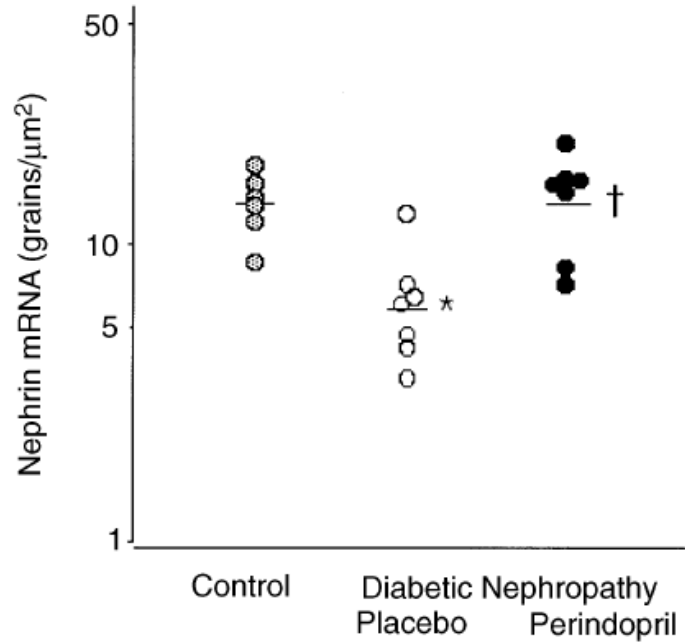
## **Glucose-Induced Reactive Oxygen Species Cause Apoptosis of Podocytes and Podocyte Depletion at the Onset of Diabetic Nephropathy**

Katalin Susztak,<sup>1</sup> Amanda C. Raff,<sup>1</sup> Mario Schiffer,<sup>1</sup> and Erwin P. Böttinger<sup>2</sup>

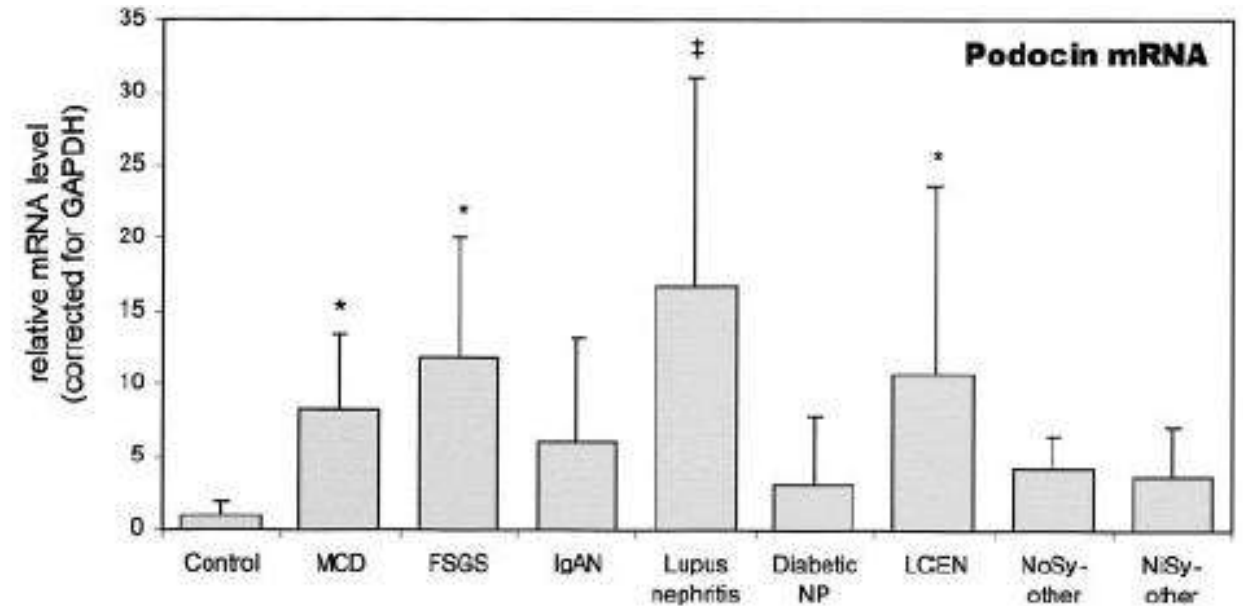
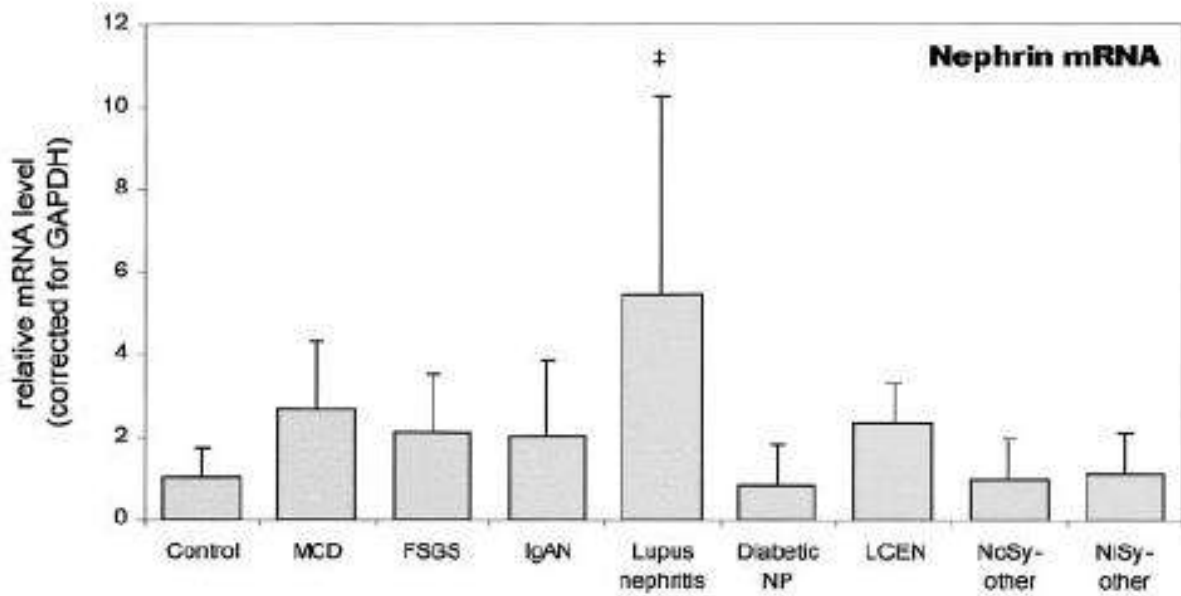
# Diyabetik Nefropati: Podositlerde Nefrin



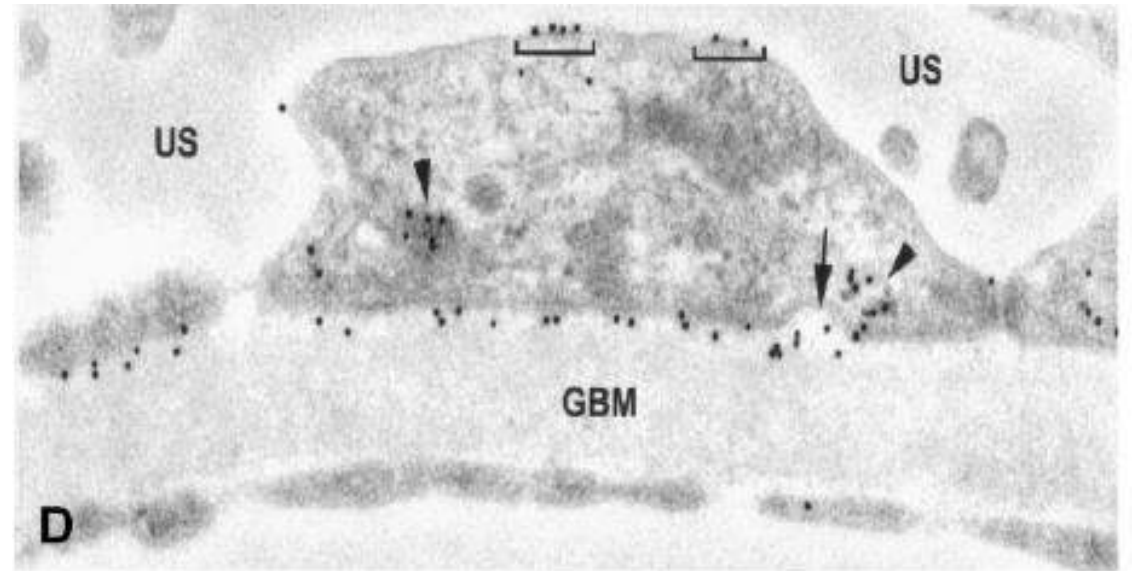
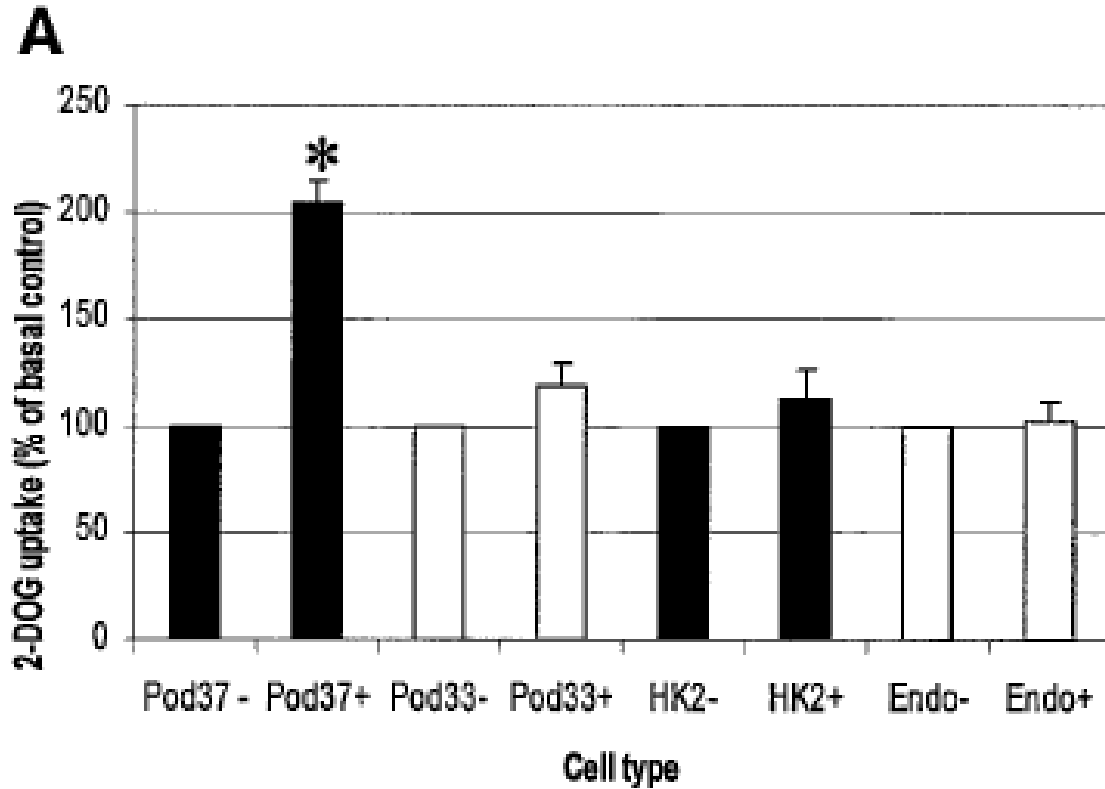
# Diyabetik Nefropati: Podositlerde Nefrin mRNA



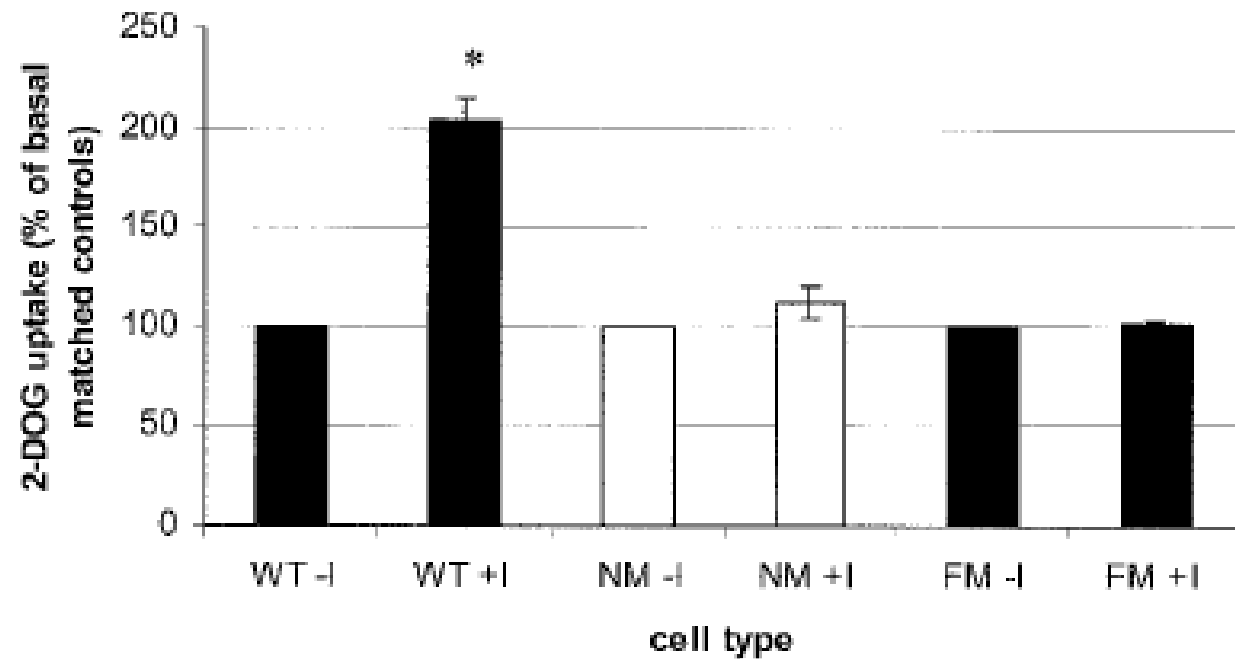
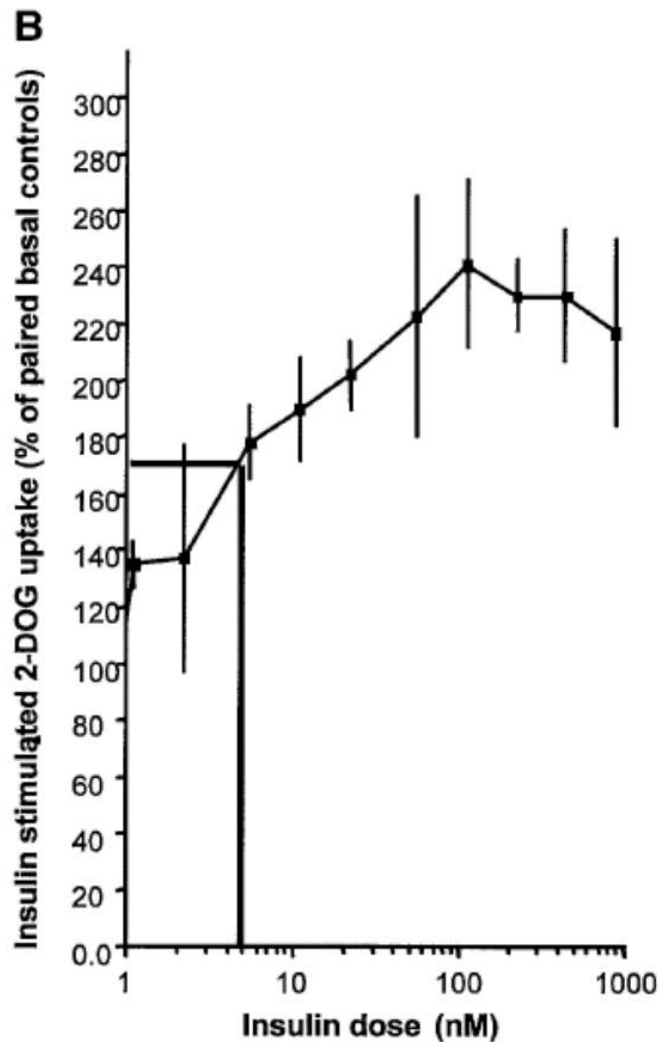
# Diyabetik Nefropati: Podositlerde Nefrin ve Podocin mRNA



# Diyabetik Nefropati: Podositlerde İnsulin Reseptörü

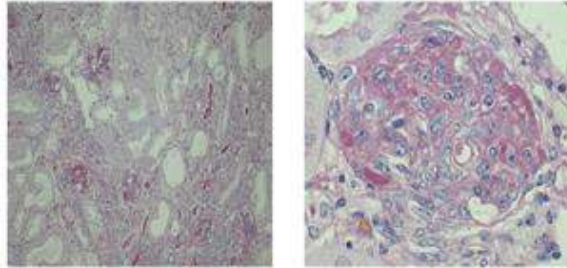


# Diyabetik Nefropati: Podositlerde İnsulin Reseptörü

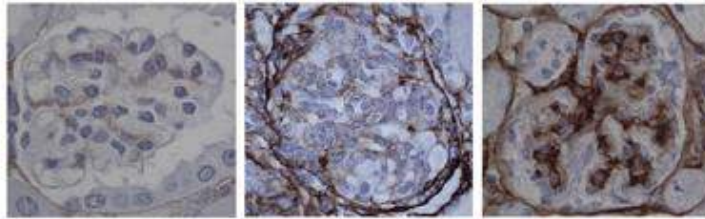




# Diyabetik Nefropati: Podositlerde İnsulin Reseptörü



Type IV collagen stain

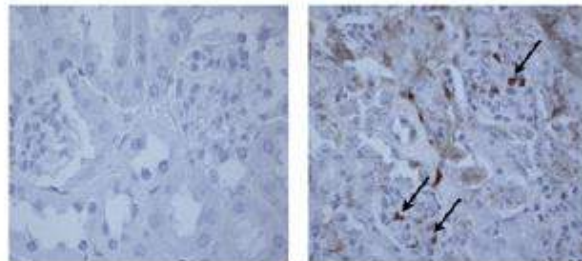


13 week control

8 week podIRKO

13 week podIRKO

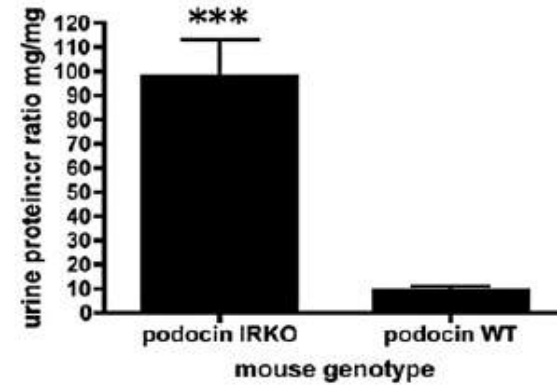
Tunel stain



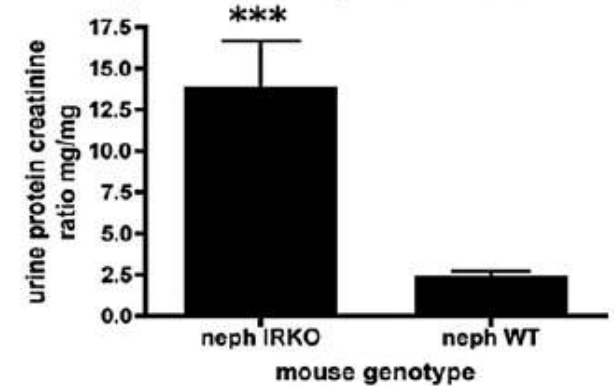
13 week control

13 week podIRKO

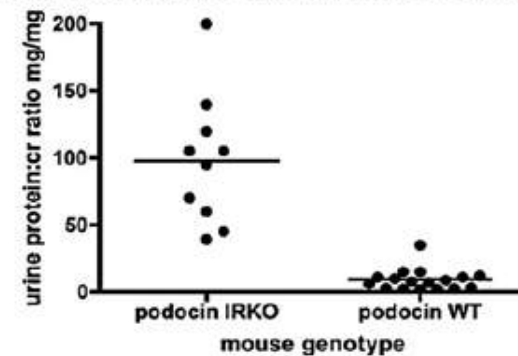
podocin cre IRKO urine protein:creatinine ratio



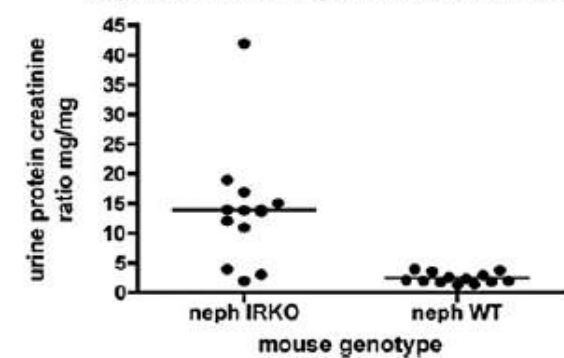
Nephrin cre urine protein:creatinine ratio



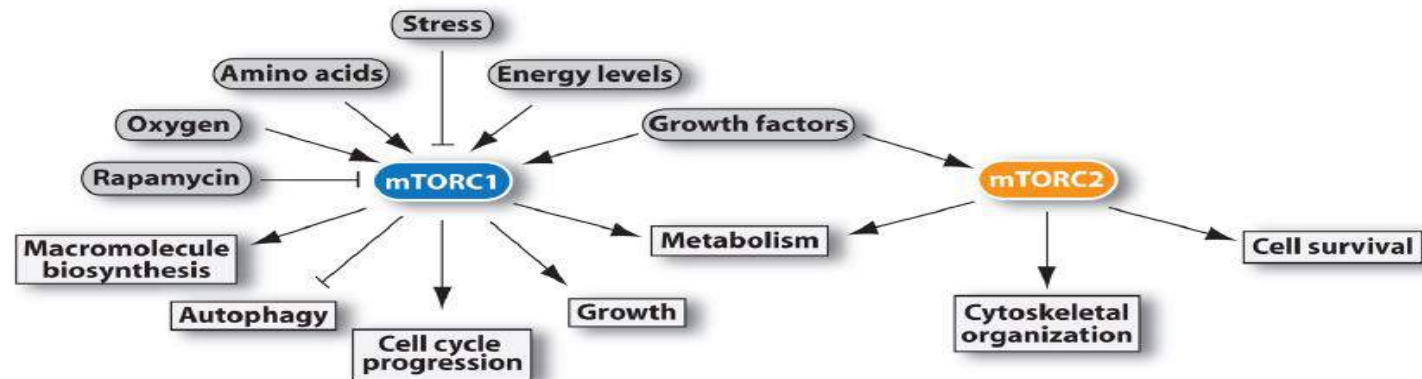
podocin cre IRKO urine protein:creatinine ratio



Nephrin cre urine protein:creatinine ratio



# Diyabetik Nefropati: Podositlerde mTORC1/2



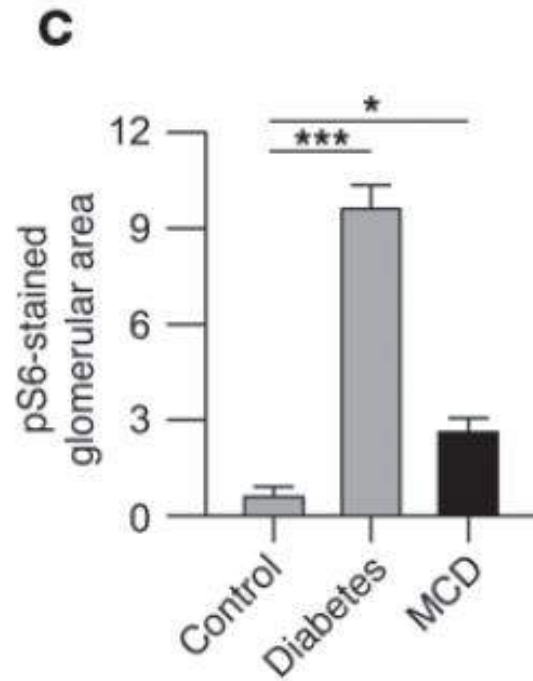
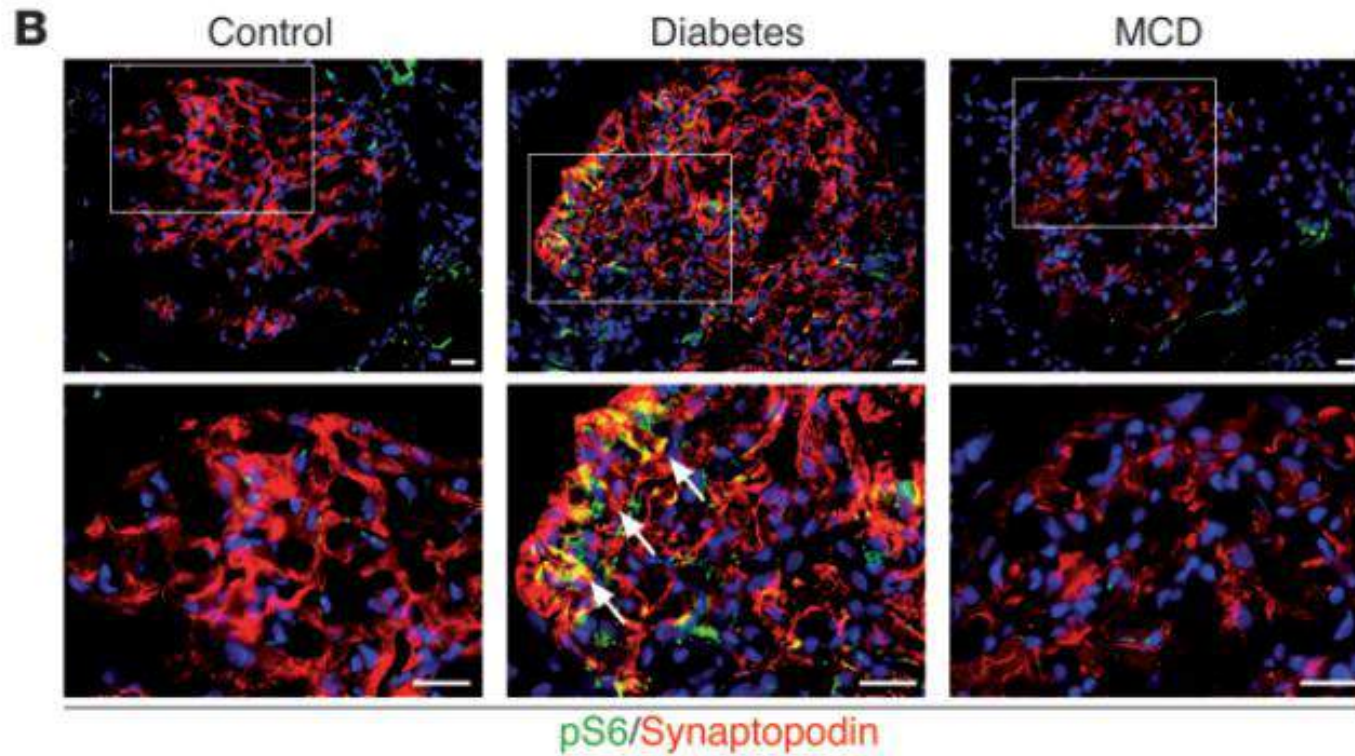
## mTORC1

- mTOR** serine/threonine kinase
- raptor** scaffold protein regulating the assembly, localization, and substrate binding of mTORC1
- pras40** mTORC1 inhibitor
- deptor** mTOR inhibitor
- mLST8** unknown function, its loss does not affect mTORC1 activity towards known substrates
- tti1** scaffold proteins regulating the assembly and the stability of mTORC1
- tel2**

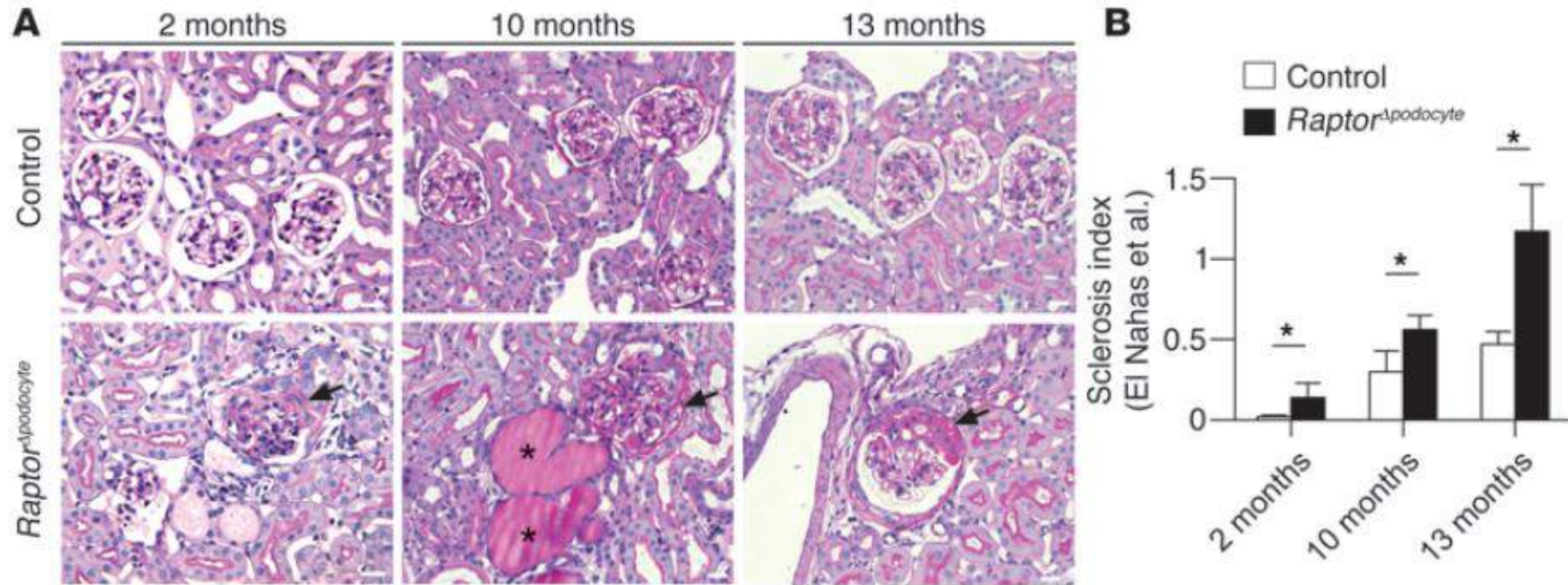
## mTORC2

- mTOR** serine/threonine kinase
- riCTOR** scaffold protein regulating the assembly and substrate binding of mTORC2
- mSin1** scaffold protein regulating the assembly of mTORC2 and its interaction with SGK1
- protor 1/2** protor1 increases mTORC2-mediated activation of SGK1
- deptor** mTOR inhibitor
- mLST8** unknown function, essential for mTORC2 activity
- tti1** scaffold proteins regulating the assembly and the stability of mTORC2
- tel2**

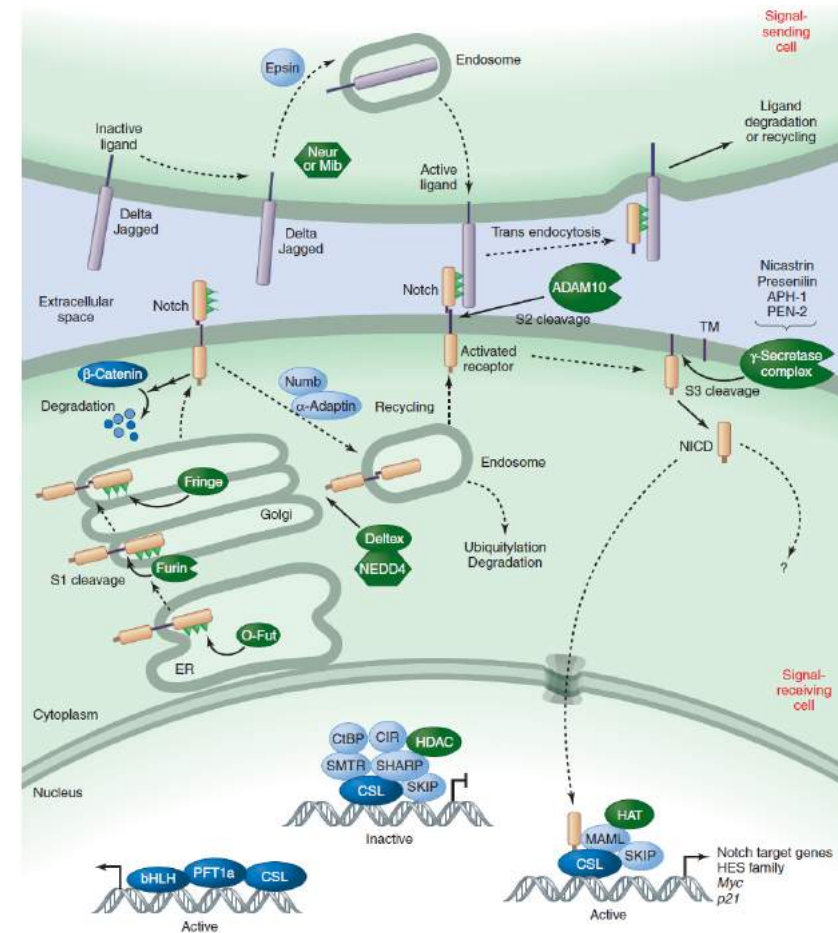
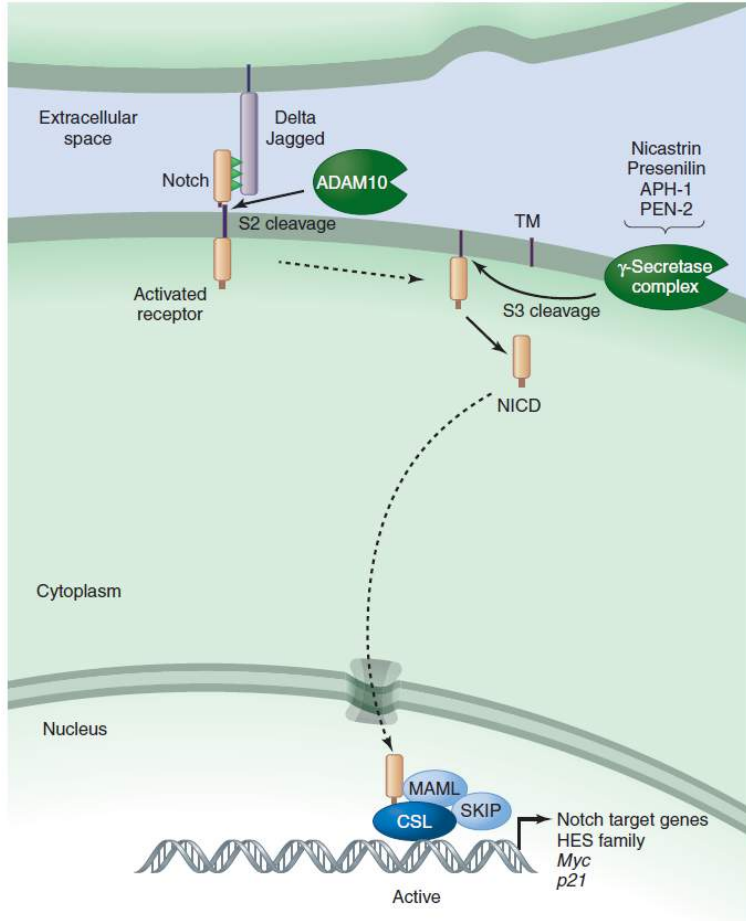
# Diyabetik Nefropati: Podositlerde mTORC1/2



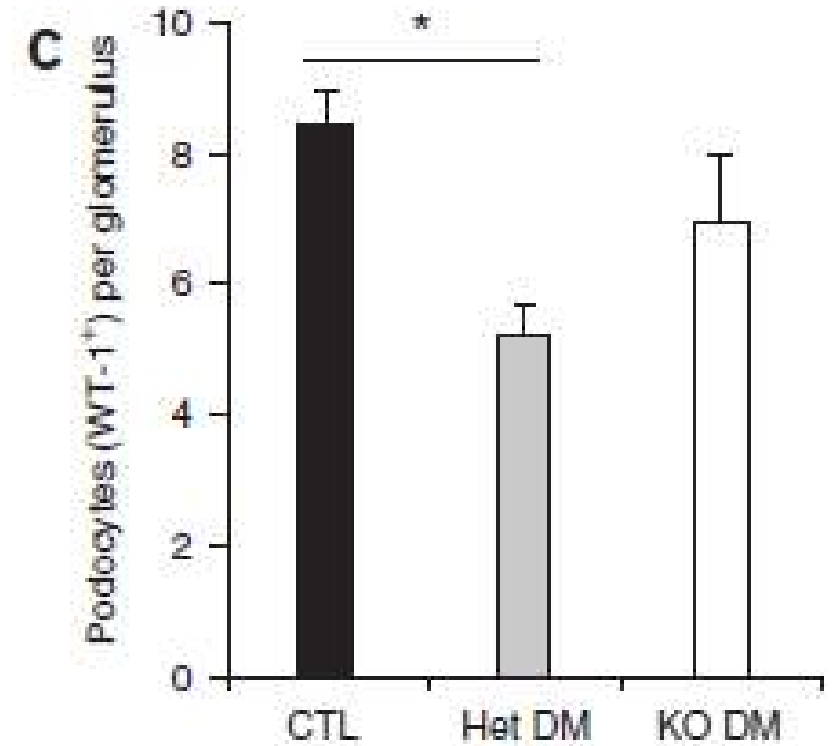
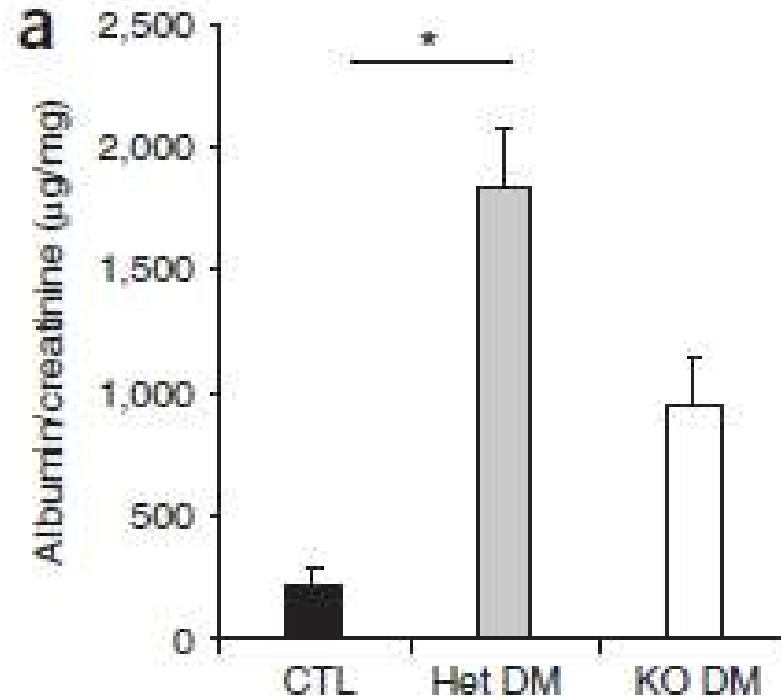
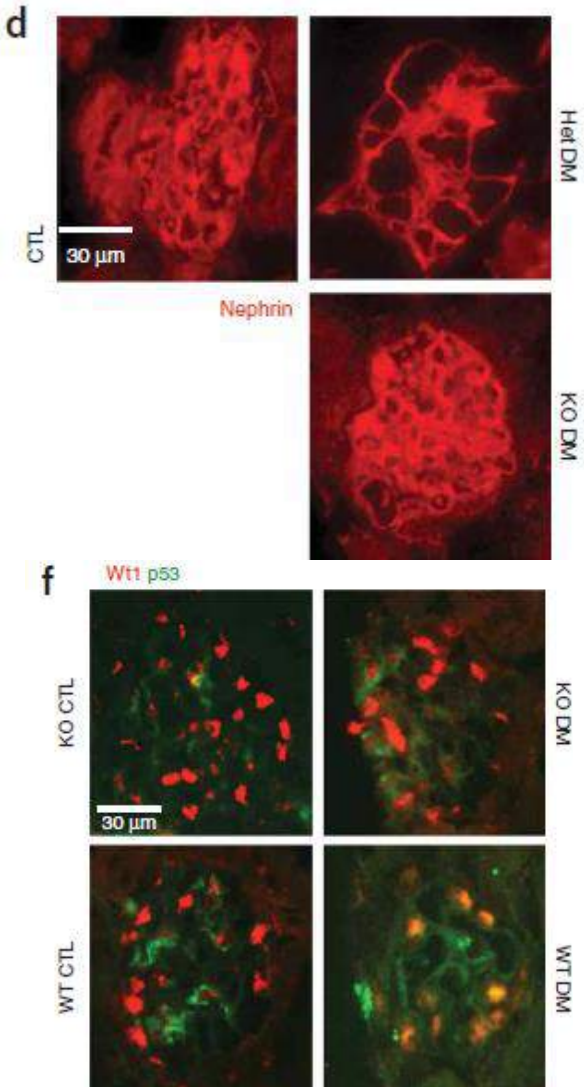
# Diyabetik Nefropati: Podositlerde mTORC1/2



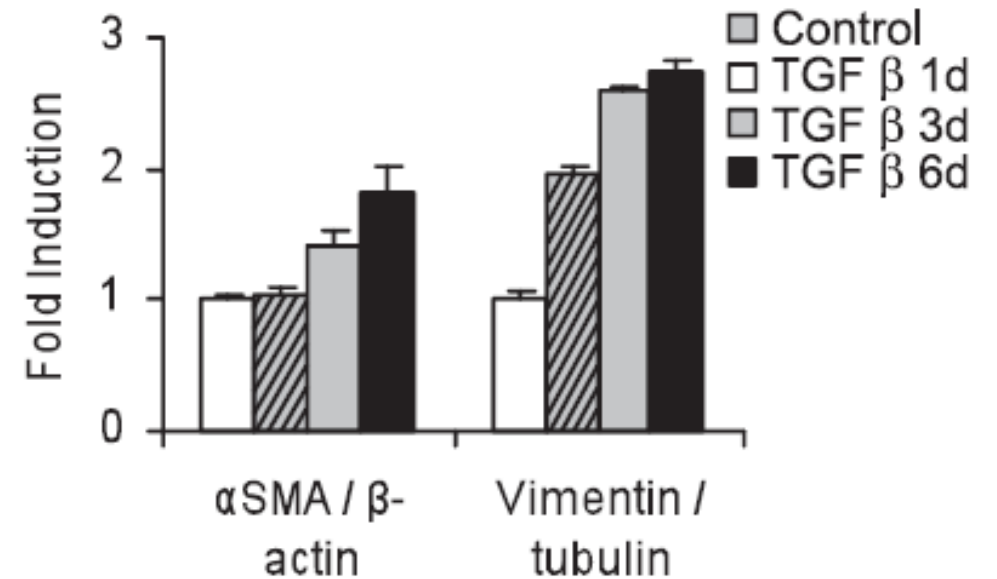
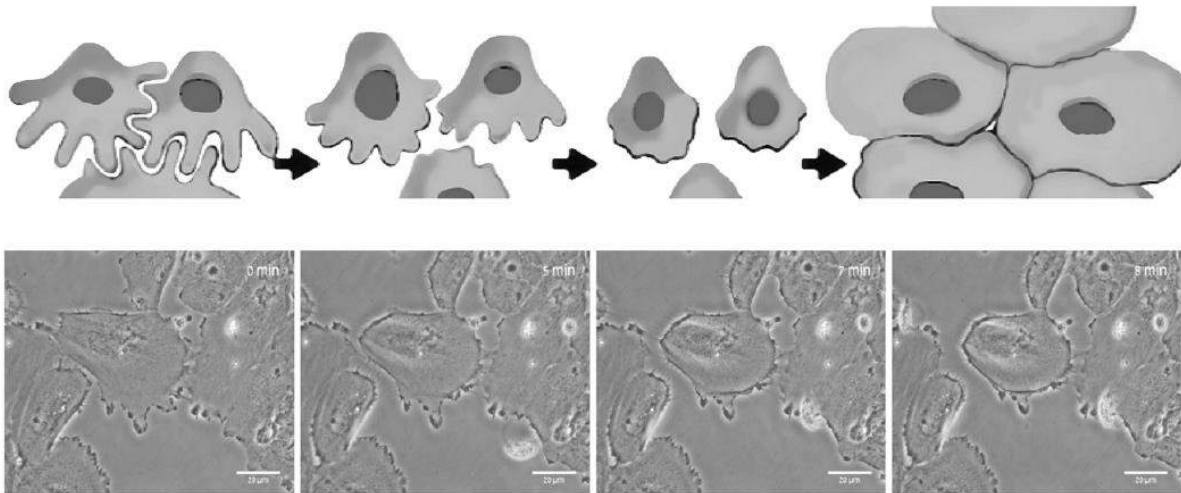
# Diyabetik Nefropati: Podositlerde Notch Sinyali



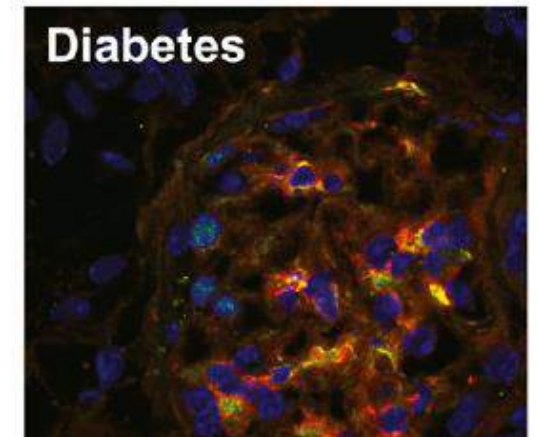
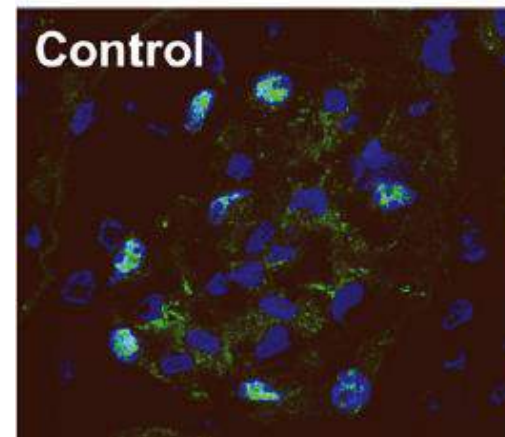
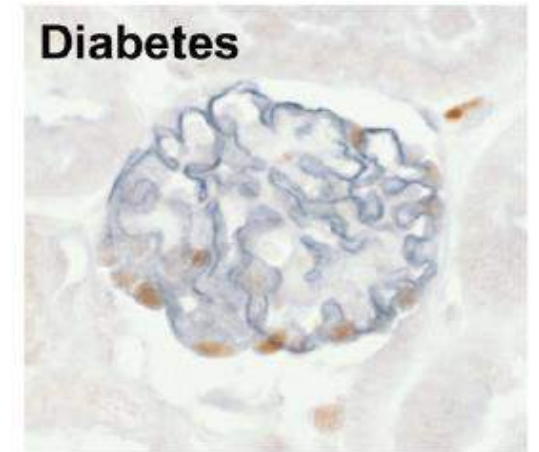
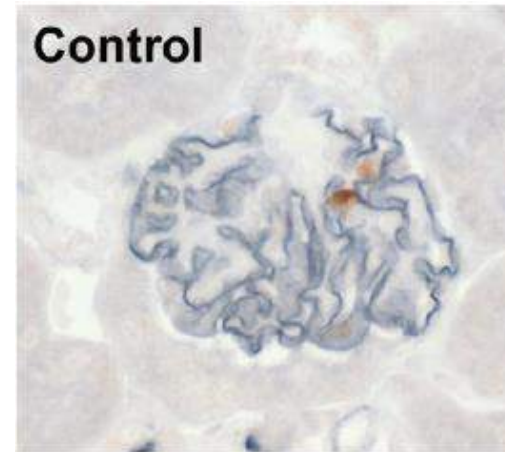
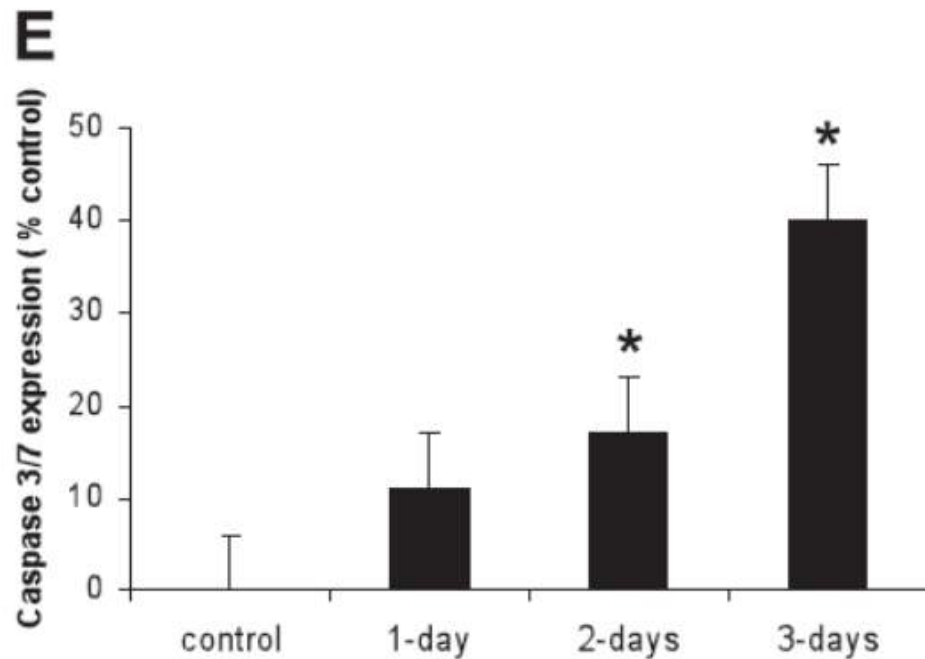
# Diyabetik Nefropati: Podositlerde Notch Sinyali



# Diyabetik Nefropati: Podosit Hasarında TGF B1



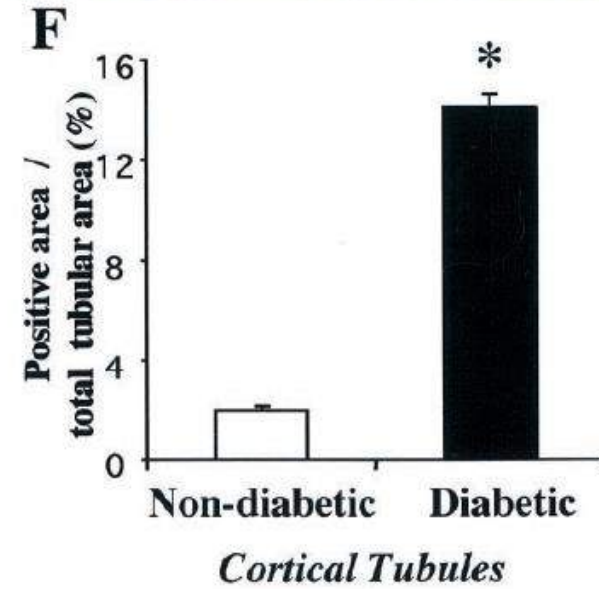
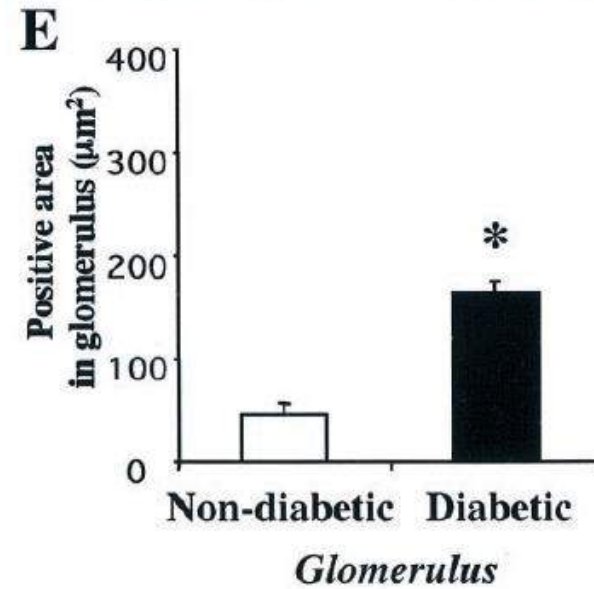
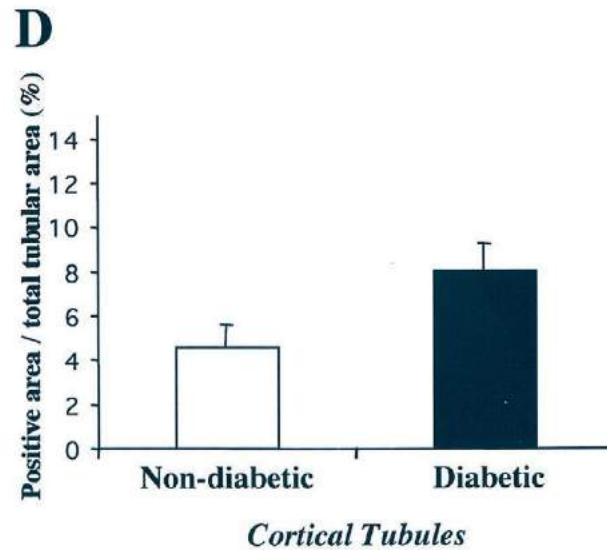
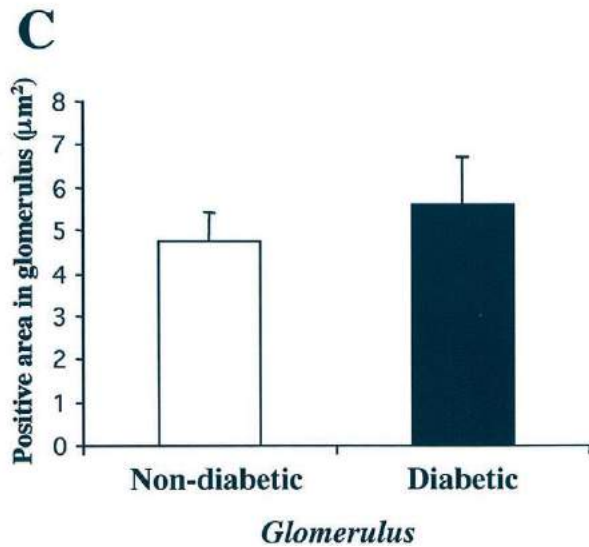
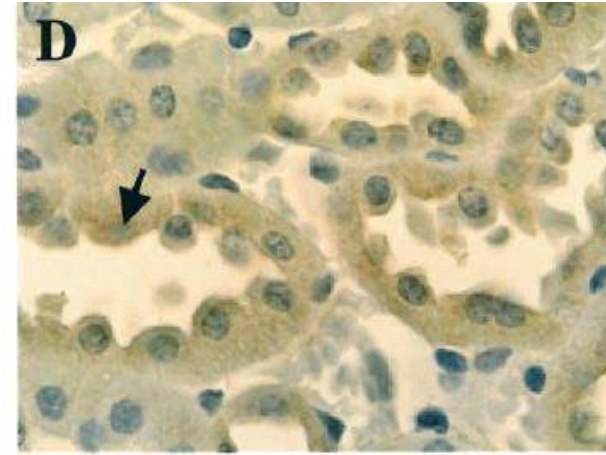
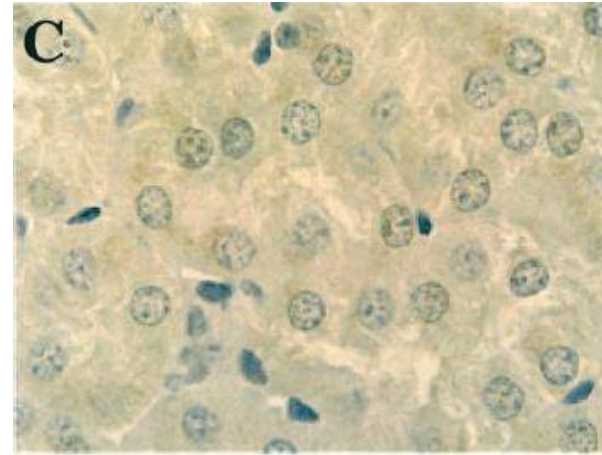
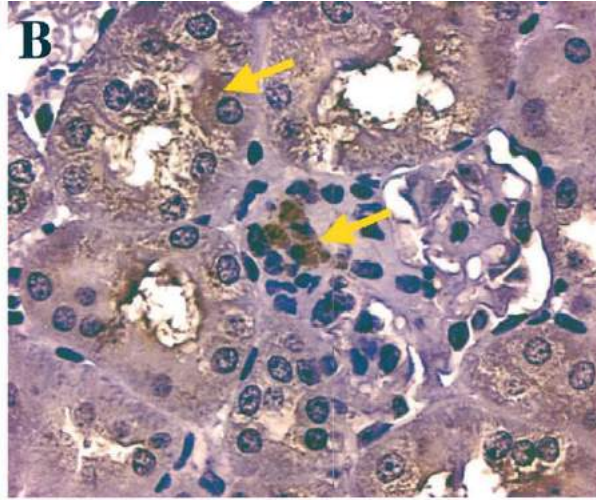
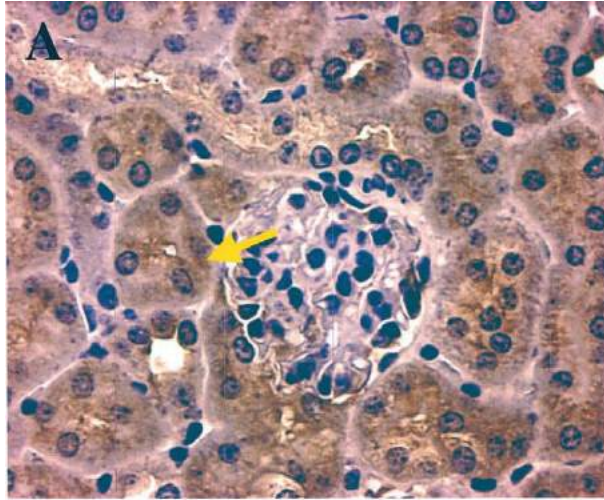
# Diyabetik Nefropati: Podosit Hasarında TGF B1



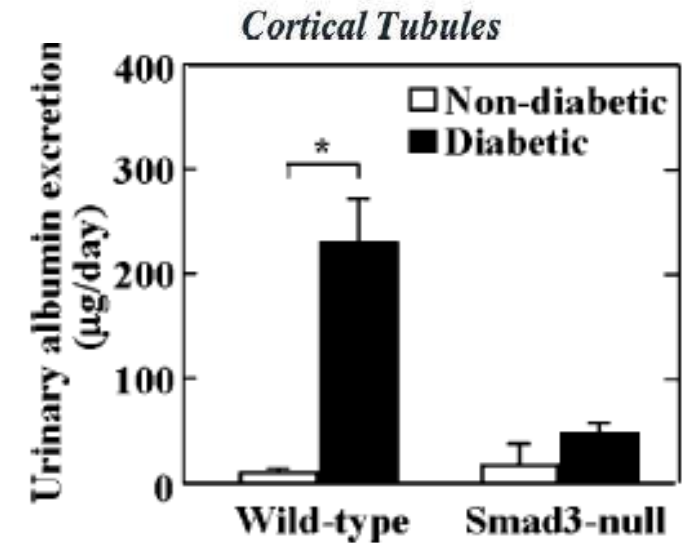
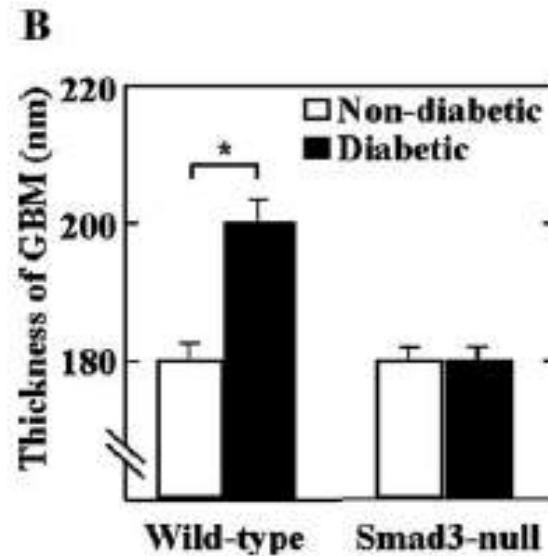
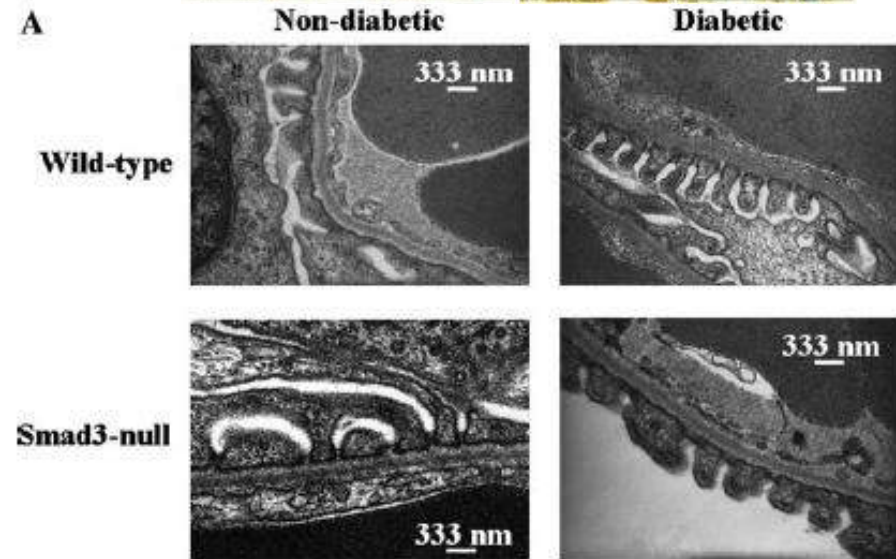
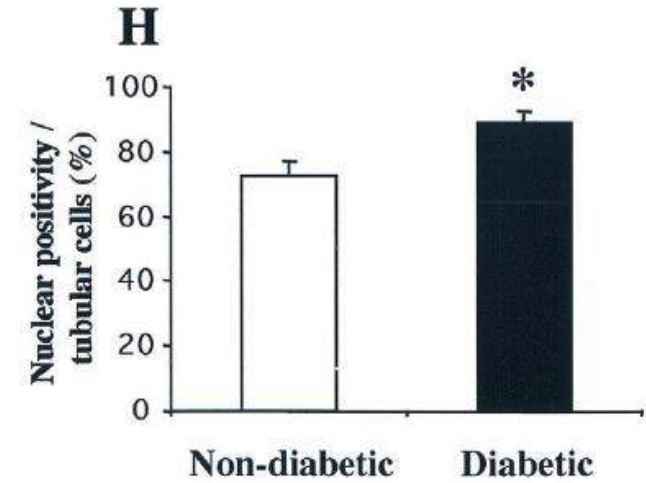
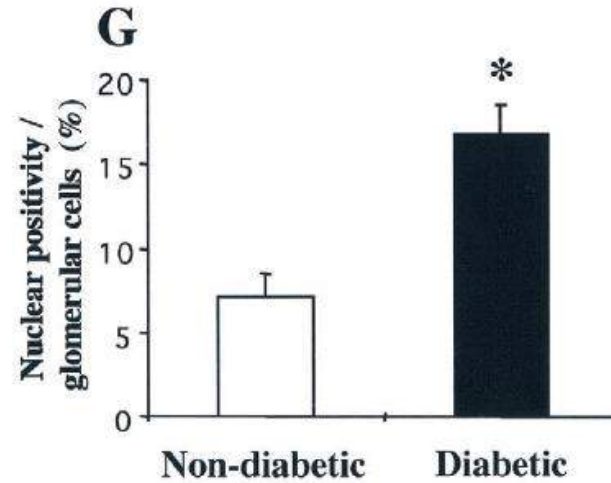
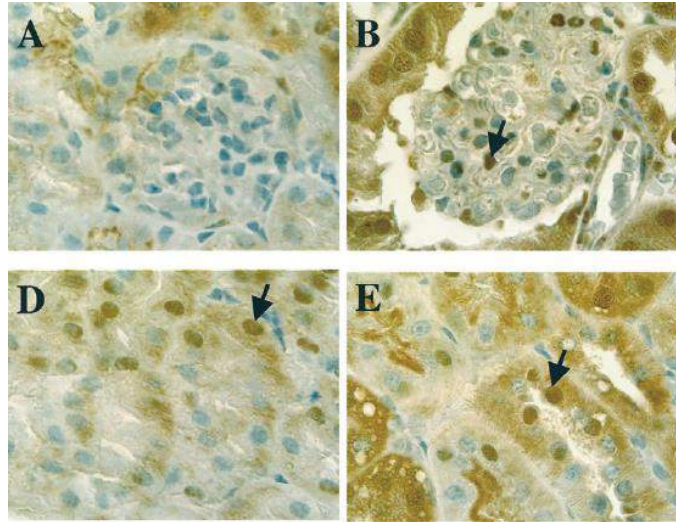
Herman-Edelstein M. Diabetes 60:1779-1788, 2011



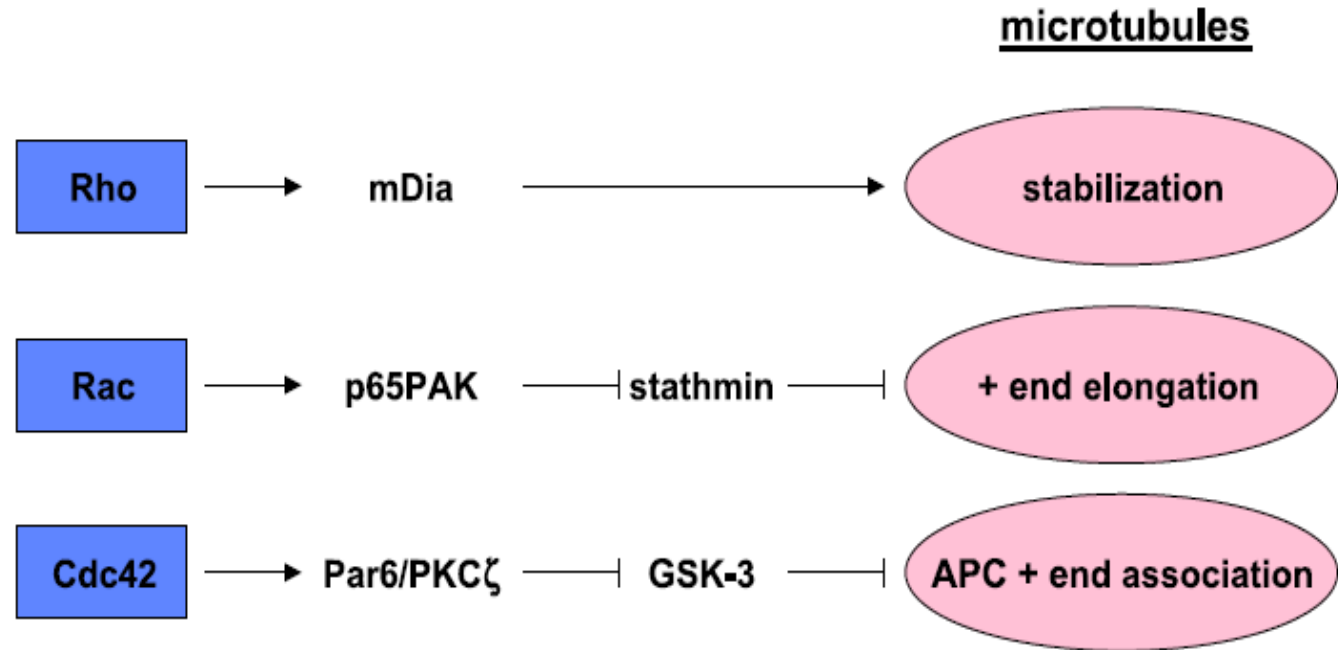
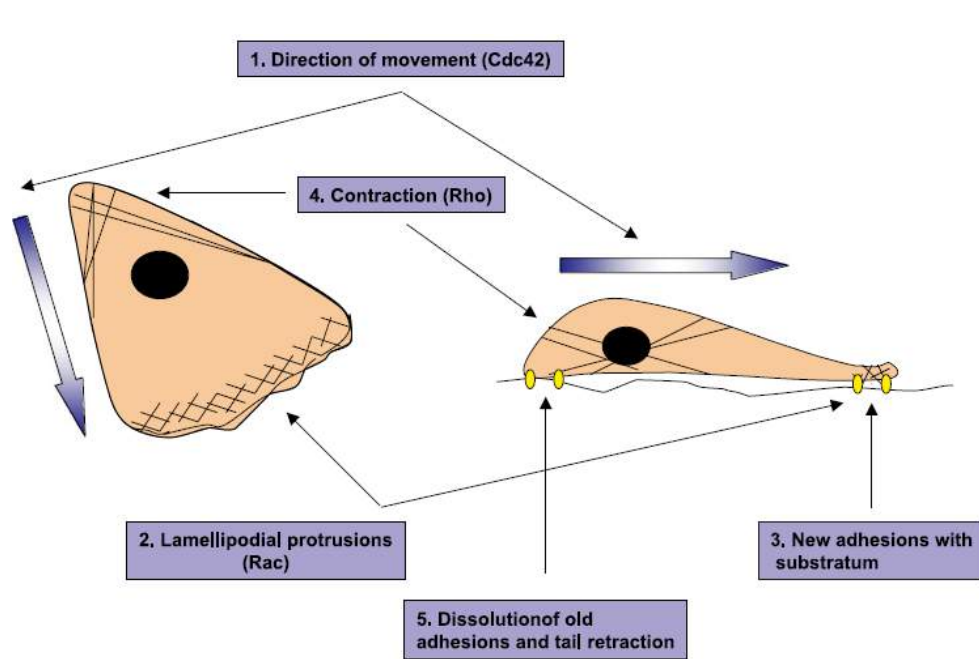
# Diyabetik Nefropati: Podosit Hasarında Smad3/TGFB1



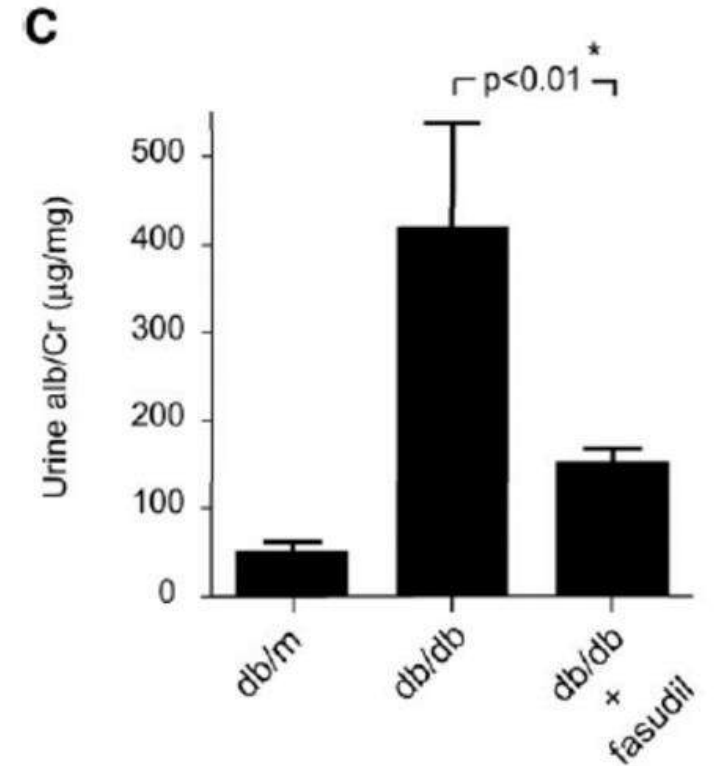
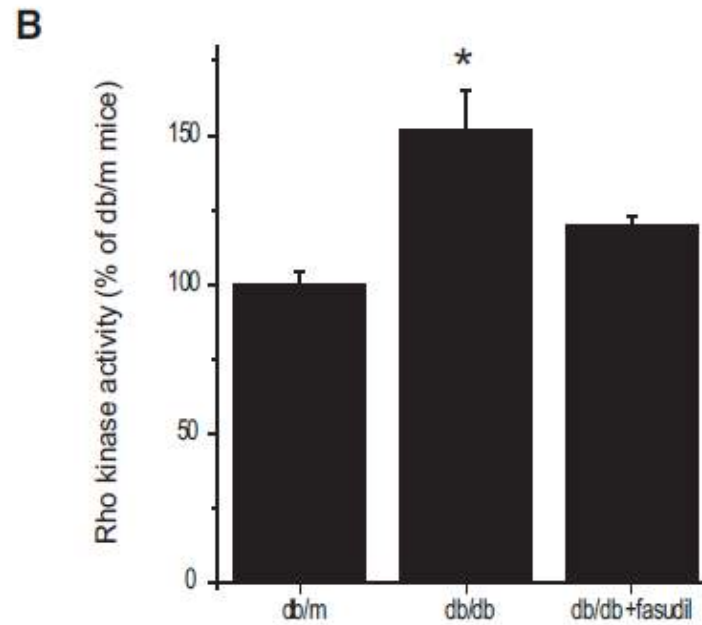
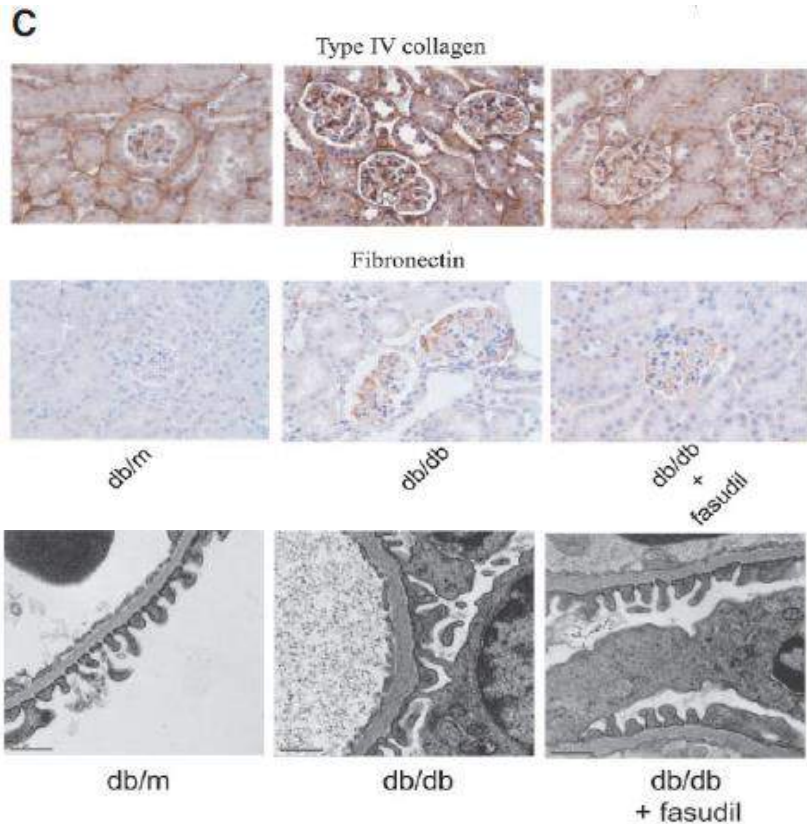
# Diyabetik Nefropati: Podosit Hasarında Smad3



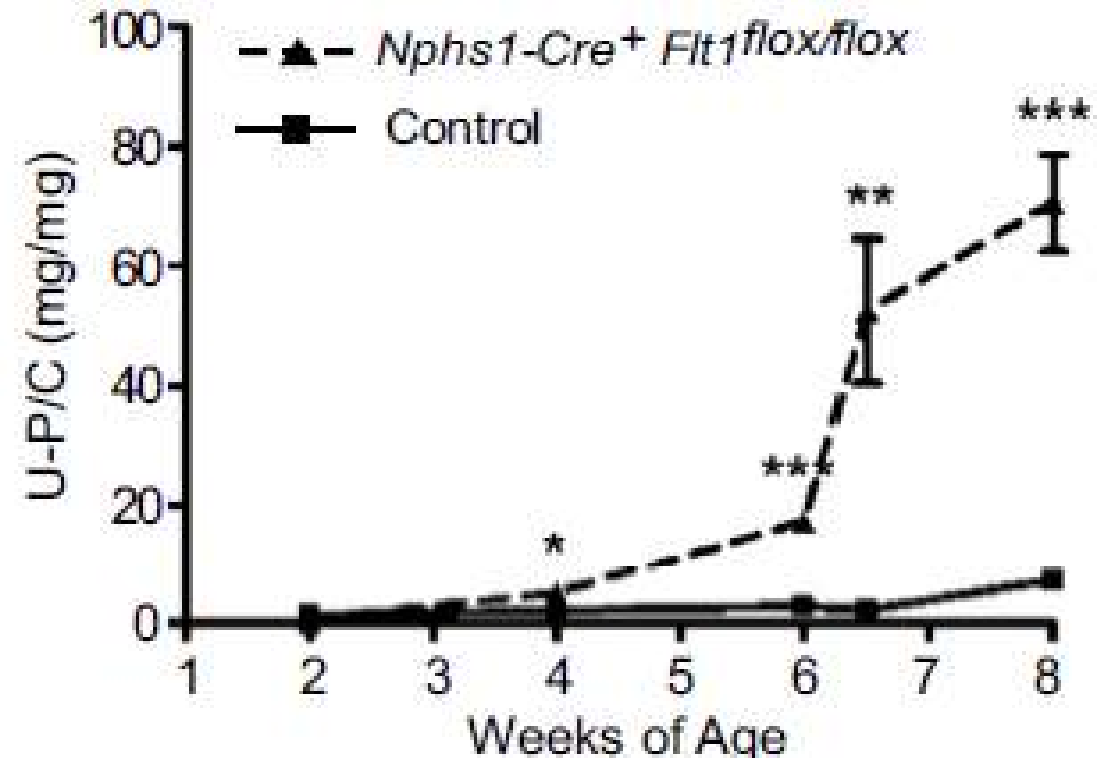
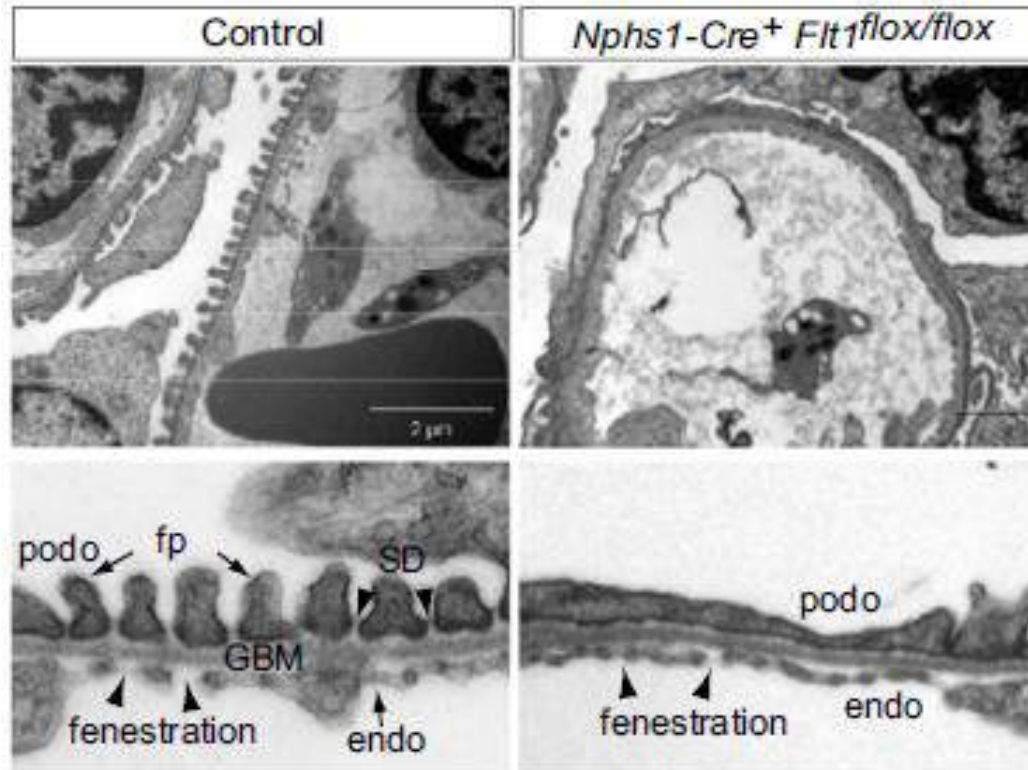
# Diyabetik Nefropati: Rho kinase



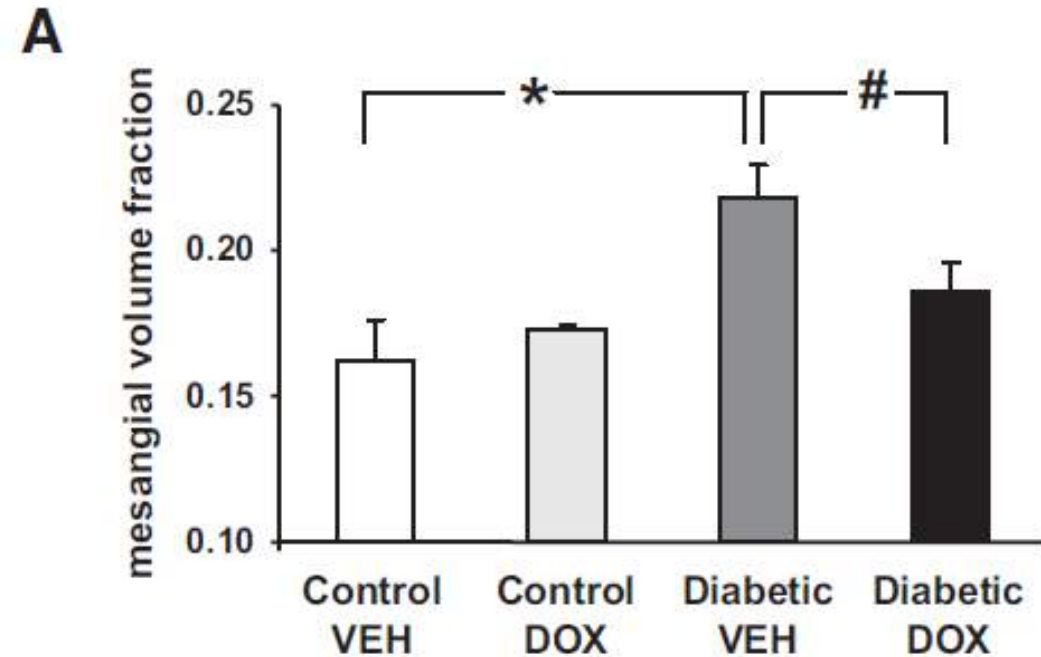
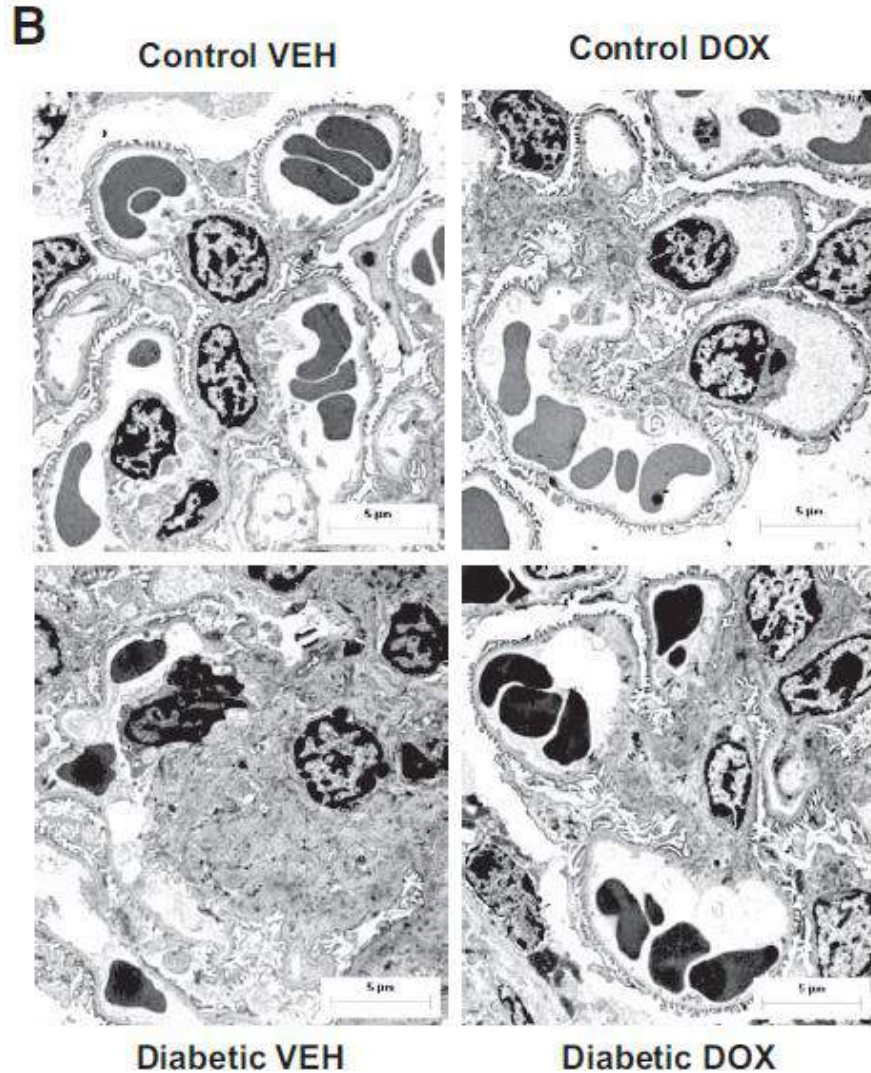
# Diyabetik Nefropati: Podosit Hasarında Rho kinase



# Diyabetik Nefropati: Podosit Hasarında Soluble FLT1

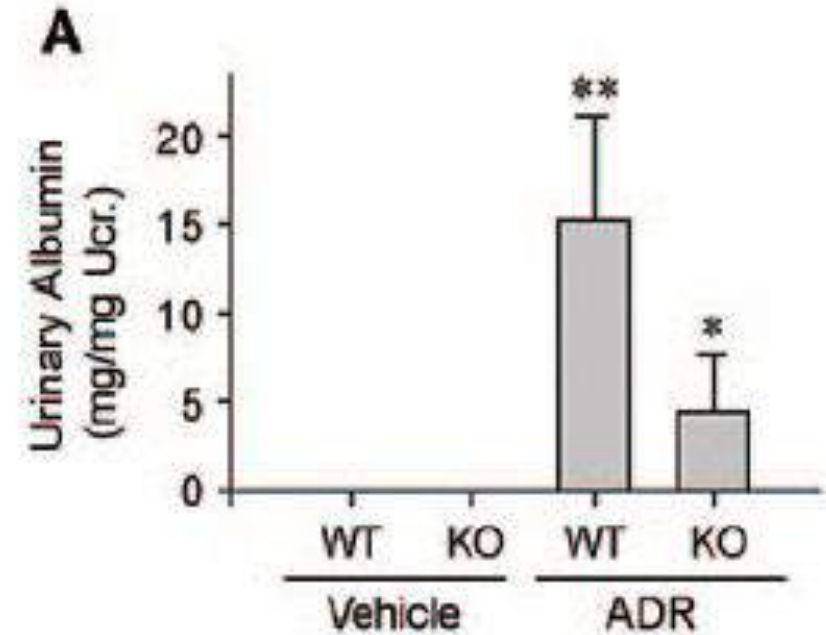
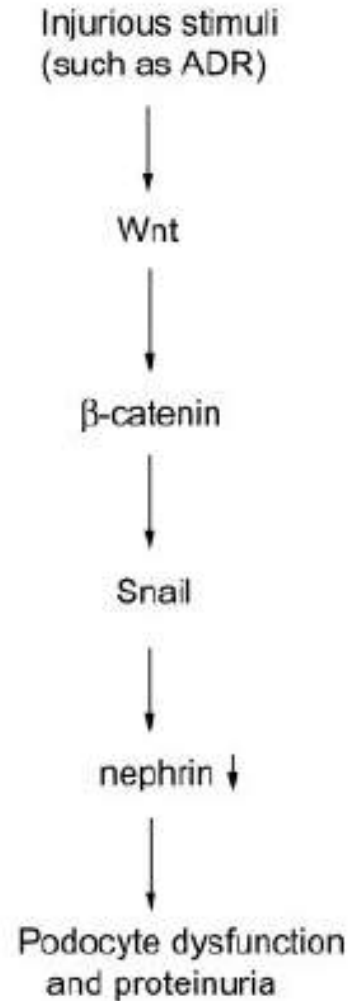
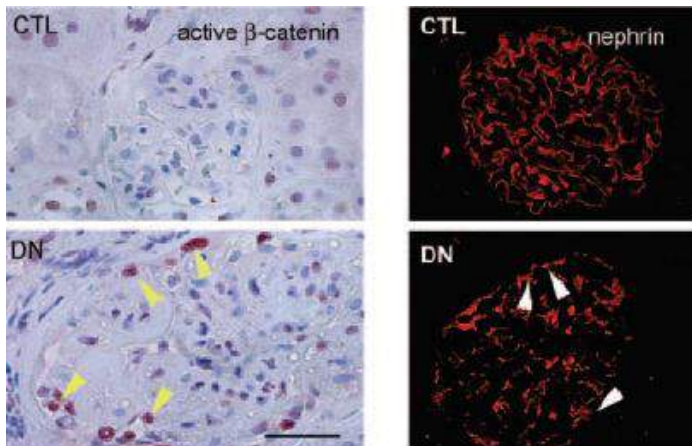
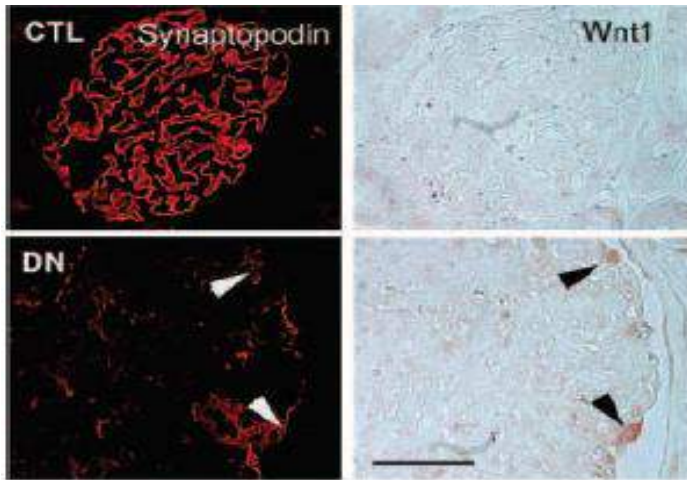


# Diyabetik Nefropati: Podosit Hasarında Soluble FLT1

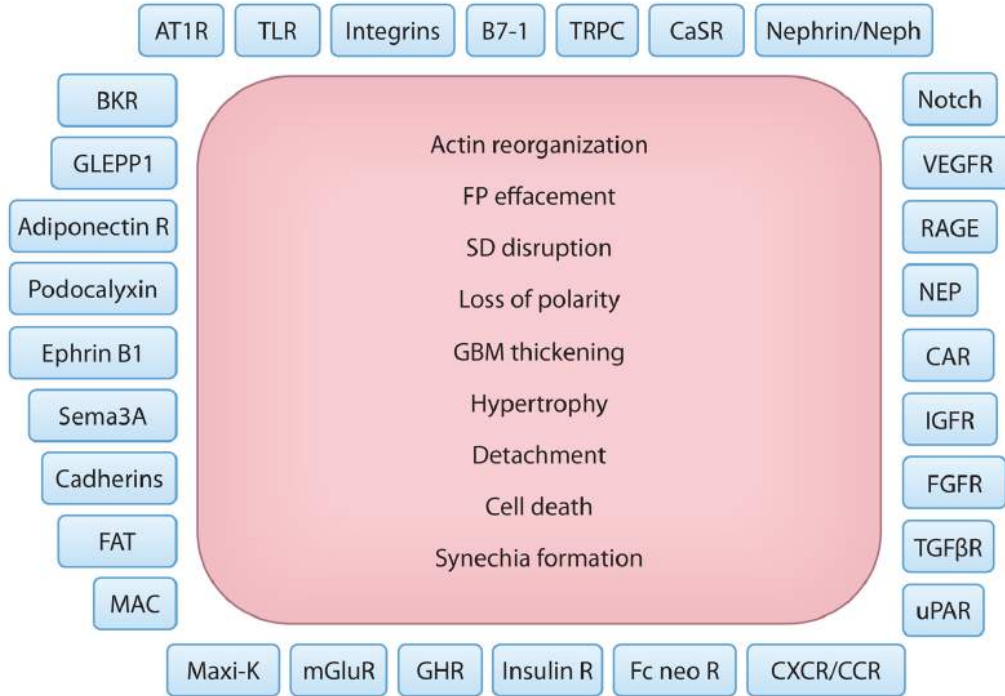


Ku CH ve ark *Diabetes* 57:2824-2833 2008,

# Diyabetik Nefropati: Podosit Hasarında Wnt/-Catenin



# Diyabetik Nefropati: Glomerüler Endotel Hücreleri



**GLİKOKALİKSDE AZALMA**

**ENDOTEL FENESTRASYONUNDA AZALMA**

**VEFG/ENOS DENGESİNDE BOZULMA**

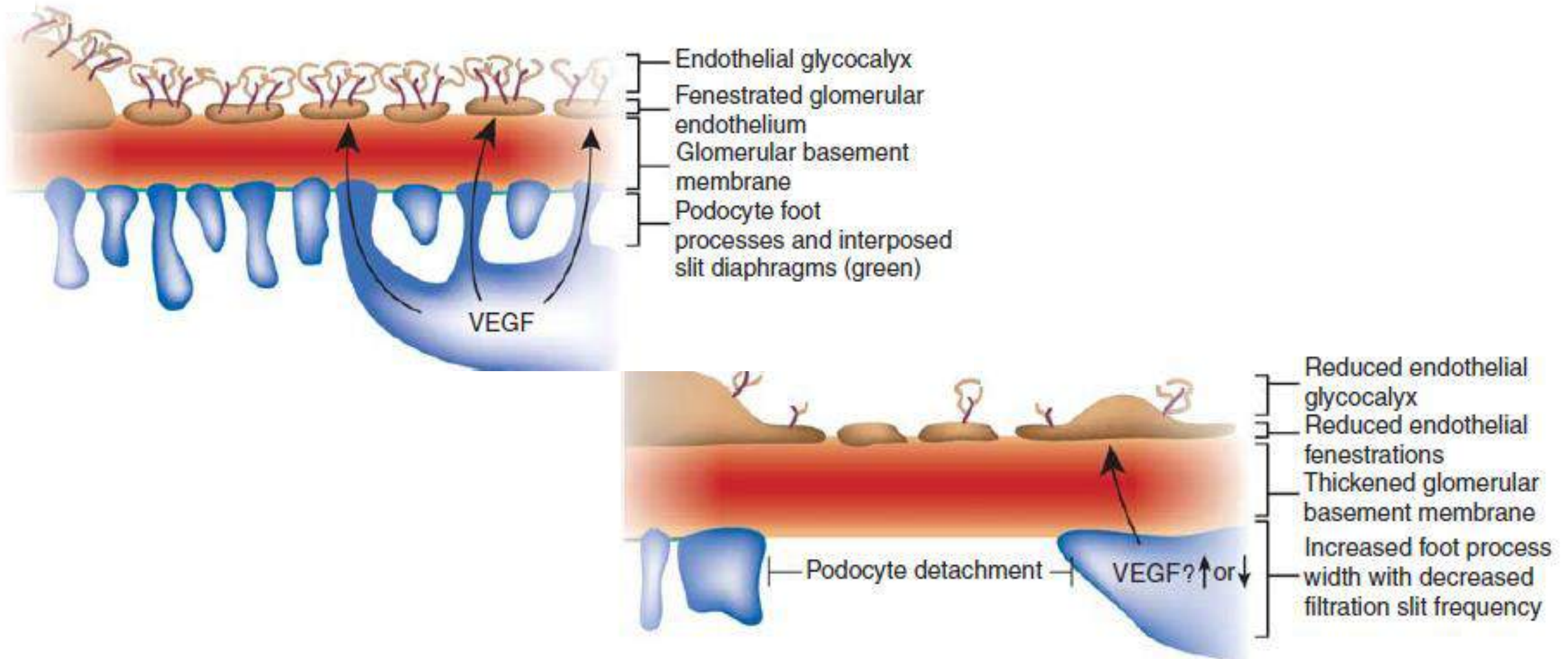
**NO ÜRETİMİNDE AZALMA**

**SUPEROKSİT ÜRETİMİNDE ARTIŞ**

**ANJİOPOETİN 1 /2 DENGESİNDE BOZULMA**

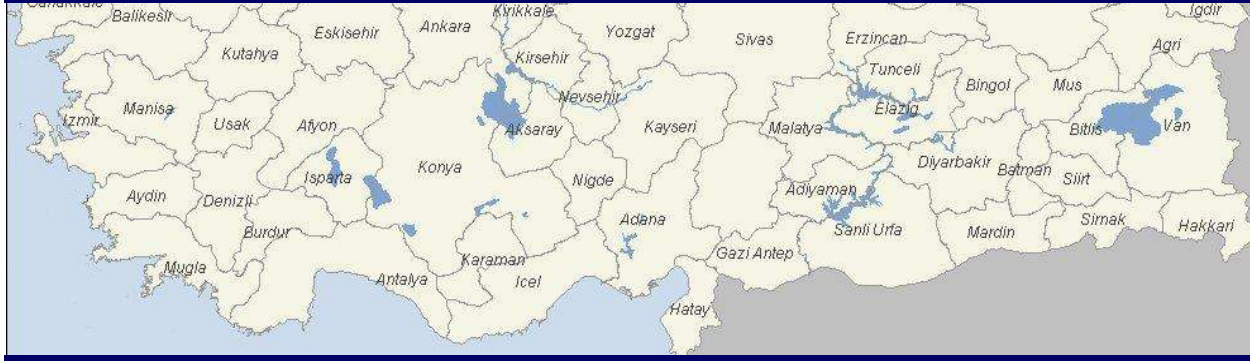
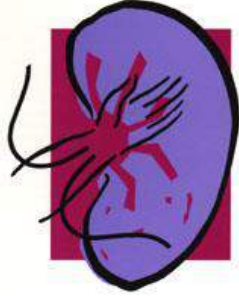
# Diyabetik Nefropati



2016 → 2017

11.000 Hasta SDBH  
tanısı alacak.



100.000 Hasta  
ilk kez geçirdikleri koroner  
olaya bağlı kaybedilecek.

